

Calcium metabolism in grey **parrots: the effects of** **husbandry.**

Thesis submitted in accordance with the requirements of
The Royal College of Veterinary Surgeons for the
Diploma of Fellowship by Michael David Stanford.

August 2005

Abstract

Hypocalcaemia is a commonly presented pathological condition in the grey parrot (*Psittacus e. erithacus*) although rarely reported in other psittacine birds. Signs in the adult birds are neurological ranging from mild ataxia to seizures responding rapidly to treatment with calcium or vitamin D₃. Captive bred grey parrot chicks suffering from calcium metabolism disorders present as juvenile osteodystrophy with characteristic bowing of the long bones and pathological fractures in severe cases. The condition is comparable to rickets in poultry. This 3 year longitudinal study reports the effects of husbandry changes on the plasma ionised calcium, 25 hydroxycholecalciferol and parathyroid hormone concentrations in two groups of 20 sexually mature healthy grey parrots.

The provision of a pellet diet with an increased vitamin D₃ and calcium content significantly increased the plasma concentration of ionised calcium and 25 hydroxycholecalciferol over a seed fed control group. The provision of 12 hours daily artificial ultraviolet radiation (UVB 315-285nm spectrum) significantly increased the plasma ionised calcium concentration independent of the diet fed. In the seed group plasma 25 hydroxycholecalciferol concentrations significantly increased after the provision of UVB radiation but not in the pellet group. In a separate study with South American parrots (*Pionus spp.*) UVB radiation did not have a significant effect on vitamin D₃ metabolism.

Blood samples were analysed from wild grey parrots recently caught in Guyana for the export pet trade. Serum ionised calcium concentrations were significantly lower in the wild birds than the captive main study group independent of the husbandry conditions employed. A significantly higher 25 hydroxycholecalciferol concentration was demonstrated in the pellet fed group over the wild grey parrots. The provision of UVB radiation resulted in significantly higher 25 hydroxycholecalciferol concentration independent of the diet fed over the wild greys.

Significantly reduced plasma ionised calcium and 25 hydroxycholecalciferol concentrations were demonstrated in 19 adult grey parrots with neurological signs. In 5 clinical cases of hypocalcaemia a significantly increased parathyroid hormone concentration was established suggesting that hypocalcaemia in grey parrots is due to nutritional secondary hyperparathyroidism. Comparative histological studies between tissues from grey parrot chicks with severe juvenile osteodystrophy and skeletally normal chicks demonstrated statistical differences between the groups. Histological changes were consistent with nutritional secondary hyperparathyroidism. Bone densitometry measurements demonstrated a statistically significant reduction in bone mineral density in osteodystrophic grey parrots compared with skeletally normal chicks. Progeny testing established that the provision of a pellet diet or UVB radiation would prevent radiographic evidence of juvenile osteodystrophy.

This study concludes that the provision of adequate dietary calcium and vitamin D₃, plus UVB radiation are essential for the prevention of disorders of calcium metabolism in captive grey parrots.

CONTENTS

Title page	1
Abstract	2
Contents	3-6
Illustrations	7-9
Acknowledgements	10
<u>Chapter 1 Introduction</u>	11-17
<u>Chapter 2 Literature Review</u>	
2.1 Control of calcium metabolism in birds	18-20
2.2 Vitamin D₃ and calcium metabolism	21-25
2.3 Metabolic functions of vitamin D₃ in birds	25-27
2.3.1 <i>Effects on mineral metabolism</i>	
2.3.2 <i>Effects on bone</i>	
2.3.3 <i>Effects on chick embryo development</i>	
2.4 Parathyroid hormone (PTH)	27-30
2.5 Calcitonin	30
2.6 Oestrogen	30-31
2.7 Prostaglandins	31
2.8 Investigating abnormalities of calcium metabolism	32-36
2.8.1 <i>Calcium</i>	
2.8.2 <i>Vitamin D₃</i>	
2.8.3 <i>Parathyroid hormone</i>	
2.9 The Effects of ultraviolet radiation on vitamin D₃ metabolism	36-39
2.9.1 <i>Introduction</i>	
2.9.2 <i>Relationship between ultraviolet light and endogenous vitamin D₃ synthesis</i>	
2.10 Disorders of calcium metabolism	39-45
2.10.1 <i>Introduction</i>	
2.10.2 <i>Hyperparathyroidism</i>	

- 2.10.3 Histological appearance of the parathyroid gland in nutritional secondary hyperparathyroidism*
- 2.10.4 Hypoparathyroidism*
- 2.10.5 Hypocalcaemia in grey parrots*

2.11 Skeletal Development in birds 46-68

- 2.11.1 Normal skeletal development in birds*
- 2.11.2 Abnormal skeletal development in birds*
- 2.11.3 Relationship between nutrition and leg disorders in poultry*
- 2.11.4 Evaluation of avian bone and its response to metabolic bone disease*

2.12 Biology of grey parrots (*Psittacus e. erithacus*) 68-69

2.13 Nutrition of captive psittacine birds 69-78

- 2.13.1 Introduction*
- 2.13.2 Calcium*
- 2.13.3 Phosphorus*
- 2.13.4 Vitamin D₃*

Chapter 3 Methodology

3.1 Main population 79-80

3.2 Study Design 81-85

3.3 Blood analysis 85-88

- 3.3.1 Handling of samples*
- 3.3.2 Biochemical analysis*
- 3.3.3 Progeny testing*

3.4 Wild parrots 88-90

3.5 Clinical cases 90-94

- 3.5.1 Hypocalcaemia in adult grey parrots*
- 3.5.2 Juvenile osteodystrophy in grey parrots*
- 3.5.3 Histopathology and Computed Tomography (CT) scanning of parrots*
- 3.5.4 Histological method*
- 3.5.5 Quantitative Histomorphometrical method*
- 3.5.6 Peripheral Quantitative Computed Tomography (pQCT) method*

3.6 Other Psittacine birds 94-97

3.7 Statistical analysis 98

Chapter 4 Results

4.1 Main study group	99-107
<i>4.1.1 Effect of dietary change on calcium metabolism</i>	
<i>4.1.2 Effect of UVB supplementation on calcium metabolism</i>	
<i>4.1.3 Comparison between dietary groups</i>	
<i>4.1.4 Correlations</i>	
<i>4.1.5 Progeny testing</i>	
4.2 Effect of gender on calcium metabolism	109-112
4.3 Clinical pathology results from hypocalcaemic adult grey parrots	113-115
4.4 Wild grey parrot samples	115-116
4.5 South American birds (<i>Pionus spp.</i>)	116-118
4.6 Pathological findings in clinical cases of juvenile osteodystrophy in grey parrots	118-126
<i>4.6.1 Radiographic and histological findings</i>	
<i>4.6.2 Histomorphometrical statistical analysis</i>	
<i>4.6.3 Peripheral Quantitative Computed Tomography (pQCT) in grey parrots</i>	
4.7 Economic cost of different husbandry protocols	127

Chapter 5 Discussion

5.1 Effect of husbandry changes on calcium metabolism in grey parrots	127-133
<i>5.1.1 Year 1 all seed fed</i>	
<i>5.1.2 Year 2 The effect of diet on calcium parameters</i>	
<i>5.1.3 Year 3 The effect of UVB radiation on calcium parameters</i>	
<i>5.1.4 Breeding performance and progeny testing</i>	
5.2 Wild birds	133-134
5.3 Captive South American birds	134-135
5.4 Correlations	135-136
5.5 Gender differences	136
5.6 Clinical cases of hypocalcaemia in adult grey parrots	136-137
5.7 Grey parrot chicks with juvenile osteodystrophy	137-140
<i>5.7.1 Histology results</i>	
<i>5.7.2 Bone mineral density</i>	

5.8 Conclusions	140
<u>Chapter 6 References</u>	141-182

Illustrations

Figure 1. An adult grey parrot (*Psittacus e. psittacus*). This captive bred bird is a friendly, intelligent pet with an excellent talent for mimicry making it a popular pet in the UK.

Figure 2. A juvenile captive bred grey parrot. The young grey parrot is distinguished from the adult birds by the dark colouration of the iris. The iris changes colour from black to pale yellow during its first year.

Figure 3. A 6 week old captive bred hand reared grey parrot with severe juvenile osteodystrophy. There is obvious bilateral bowing of the tibiotarsus. Radiography revealed evidence of osteodystrophy in wings, legs and spine with numerous pathological fractures. The bird was euthanased on humane grounds. The bird had been hand reared on a cereal diet with no additional calcium or vitamin D₃ supplementation.

Figure 4. A dorsal-ventral radiograph of an 8 month old captive grey parrot. The radiograph indicates evidence of juvenile osteodystrophy with bowing in both tibiotarsi. There is also obvious distortion in both wings. The radiographs were taken as part of a post purchase examination and the bird was otherwise healthy.

Figure 5. A dorsal-ventral radiograph of an egg bound grey parrot. The film demonstrates the presence of medullary bone in mature female birds. The characteristic fluffy appearance of medullary bone can be visualised in the medullary cavity of the femur. The bird was diagnosed with egg peritonitis and a salpingohysterectomy was performed to remove the egg.

Figure 6. Parathyroid gland from a juvenile peregrine falcon (*Falco peregrinus*) with nutritional secondary hyperparathyroidism. The bird presented with bilateral pathological fractures of the tibiotarsi. The gland demonstrates hypertrophy of the chief cell with evidence of vacuolation throughout the gland. (Haematoxylin and eosin, 20X magnification main image, insert 2X magnification).

Figure 7. Normal histological appearance of the avian growth plate. The growth plate consists of 5 distinct layers.

Figure 8. Normal radiographic appearance of the avian growth plate. This demonstrates that the avian growth plate consists of unossified cartilage not visualised on radiographs.

Figure 9. Traditional method of hand rearing parrots. The birds are kept individually in small plastic containers. The birds would not be expected to receive the support from their siblings that might occur in a normal nest.

Figure 10. Grey parrots hand reared in small groups in artificial nests. This might be expected to provide more support to the rapidly growing bones than rearing the birds individually.

Figure 11. Growth plate of a 6 week old grey parrot with juvenile osteodystrophy. There is an increase in the length of the hypertrophic zone of the growth plate.

Figure 12. Humerus, radius and ulna from a grey parrot euthanased due to severe juvenile osteodystrophy. The bones are very flexible with replacement of normal bone by fibrous tissue.

Figure 13. Cortical bone of the humerus from a grey parrot with juvenile osteodystrophy. The arrows indicate peripheral unmineralised osteoid seams, consistent with osteodystrophy. Fibroblasts fill the space between the two areas of bone, consistent with fibrous osteodystrophy. (Haematoxylin and eosin, 200X).

Figure 14. Subchondral medullary bone from the humerus of a grey parrot with juvenile osteodystrophy. Significant numbers of fibroblastic spindle-shaped cells separate trabeculae, which are lined by numerous osteoclasts (arrows). These lesions are consistent with secondary hyperparathyroidism. (Haematoxylin and eosin 200X).

Figure 15. Medullary bone from the tibiotarsus of a grey parrot with juvenile osteodystrophy. The medullary bone in the tibiotarsus is lined by plump (active) osteoblasts. Centrally the trabeculae are mineralised but they have pale-staining eosinophilic peripheral seams of unmineralised osteoid. The numbers of osteoclasts (arrows) are increased on mineralised and unmineralised surfaces.

Figure 16. Juvenile osteodystrophy in a 12 week old hand reared grey parrot. There is severe bowing of the tibiotarsus.

Figure 17. Radiograph of the grey parrot in figure 16. There is a pathological fracture of the tibiotarsus. The bird was euthanased due to the severity of the condition.

Figure 18. Medullary bone from the tibiotarsus of the grey parrot in figure 16. The trabeculae have markedly irregular margins lined by increased numbers of osteoclasts. (Haematoxylin and eosin, 200X).

Figure19. Traditional seed mix. Although this type of seed mix is imbalanced and encourages selective feeding it is still the most common diet used by aviculturists in the UK.

Figure 20. Seed mix used in the main study (Tidymix Diet).

Figure 21. Pellet diet used in main study (Harrison's High Potency Course diet).

Figure 22. Post purchase check ventral-dorsal radiograph on a juvenile grey parrot. This demonstrates the use of the standard marker bone.

Figure 23. Post purchase check lateral radiograph of a grey parrot chick. This demonstrates the appearance of the marker bone on a radiograph to help standardise the interpretation of the films. This bird has evidence of osteodystrophy in the tibiotarsus.

Figure 24. A group typical of the South American birds used in the study (*Pionus spp.*).

Figure 25. Pulse based mix used to feed the South American birds in the study. The diet was supplemented with a vitamin and mineral mix (Avimix, Vetark Products, Winchester, UK).

Figure 26. A typical ventral dorsal radiograph from a pellet fed grey parrot demonstrating normal skeletal growth in the species.

Figure 27. A typical lateral radiograph from a pellet fed grey parrot demonstrating normal skeletal growth in the species.

Figure 28. A typical ventral-dorsal radiograph from a grey parrot with juvenile osteodystrophy demonstrating abnormal skeletal growth. Numerous bilateral structural changes are visible in the humerus, radius, ulna, femur, tibiotarsus, synsacrum and spine.

Figure 29. A typical lateral radiograph from a grey parrot with juvenile osteodystrophy demonstrating abnormal skeletal growth. Numerous bilateral structural changes are visible in the humerus, radius, ulna, femur, tibiotarsus, synsacrum and spine.

Figure 30. Section of cortical bone from a skeletally normal 12 week old grey parrot. (Haematoxylin and eosin 200X).

Figure 31. Section of cortical bone from a grey parrot with juvenile osteodystrophy. There is a loss of normal osteoid and replacement with fibrous tissue especially in the periosteal region compared with figure 30. (Haematoxylin and eosin, 200X).

Figure 32. Section of cortical bone stained specifically for minerals from a grey parrot with juvenile osteodystrophy. The section demonstrates the reduction in mineralisation of the bone. (Von Kossa, 200X).

Figure 33. Parathyroid gland from a 6 week old grey parrot with juvenile osteodystrophy. The gland is obviously enlarged and vacuolated consistent with hyperparathyroidism. The adjacent thyroid gland is shown for comparison. (Haematoxylin and eosin, 20X).

Tables

1. As fed analysis of diets used in study.
2. Standard blood health profile performed on each bird.
3. As fed analysis of pulse diet used with South American birds.
4. Effect of dietary change on calcium parameters.
5. Effect of UVB light on calcium parameters.
6. Comparison of dietary groups 12 months after dietary change.
7. Comparison of dietary groups 12 months after provision of UVB lights.
8. Correlations between calcium parameters investigated during study.
9. Incidence of radiographic evidence of juvenile osteodystrophy in progeny produced by the study group.
10. Effect of gender on ionised calcium concentrations in seed group.
11. Effect of gender on total calcium concentrations in seed group.
12. Effect of gender on 25 hydroxycholecalciferol concentrations in seed group.
13. Effect of gender on parathyroid hormone concentrations in seed group.
14. Effect of gender on ionised calcium concentrations in pellet group.
15. Effect of gender on total calcium concentrations in pellet group.
16. Effect of gender on 25 hydroxycholecalciferol concentrations in pellet group.
17. Effect of gender on parathyroid hormone concentrations in pellet group.
18. Clinical pathology results from adult grey parrots with clinical signs of hypocalcaemia.
19. Response of plasma ionised calcium following treatment for hypocalcaemia.
20. Calcium metabolism concentrations from wild grey parrots.
21. Effect of different UVB conditions on calcium parameters in South American parrots (*Pionus spp.*).
22. Effect of seasonality on calcium parameters in South American parrots (*Pionus spp.*).
23. Histomorphometrical analysis of tibiotarsus in juvenile grey parrots.
24. Histomorphometrical analysis of humerus in juvenile grey parrots.
25. pQCT analysis of bone mineral density in tibiotarsus and humerus.

Acknowledgements

I would like to acknowledge the following organisations for financial assistance that made the extensive laboratory studies possible for the preparation of this thesis:

Harrison's International Bird Foods, Nebraska, US.

The Royal College of Veterinary Surgeons Small Grant Trust, London, UK.

MacDonald Laboratories, Tarporley, UK.

I am grateful to my advisors Nigel Harcourt-Brown and Professor Jonathan Elliott for their advice and encouragement in the preparation of this thesis from conception to completion. I would like to thank colleagues at Birch Heath Veterinary Clinic for helping with sample collection during the study and Professor Andrew Guppy-Adams for assisting with the statistical calculations. I would also like to thank Dr Janet Patterson- Kane and Mary Tyler for the histological studies and the bone density examination of the juvenile grey parrots. A huge debt of gratitude is owed to Rebecca and Chris Taylor for their hard work and cooperation maintaining the birds. Finally I would personally like to thank both Nigel Harcourt -Brown and Dr. Greg Harrison for their unerring enthusiasm, support and passion to get this work to completion.

The thesis is dedicated to my wife, Kate.

CHAPTER 1

Introduction

The grey parrot (*Psittacus e. erithacus*) is wide spread throughout equatorial Africa. It is the second most commonly traded psittacine bird in the world pet trade, desired mainly because of its excellent ability as a mimic (Collar N.J. 1997). Captive breeding of the grey parrot has increased dramatically during the last decade as popularity of the species continues to increase (figures 1 & 2). Hypocalcaemia is a commonly recognised syndrome in captive grey parrots although the aetiology remains unconfirmed (Roskopf W.J. & others 1985). Clinical signs of hypocalcaemia in adult grey parrots are generally neurological in nature. These signs can be attributed to low plasma ionised calcium concentrations ranging from slight ataxia and head twitching to seizures. The condition usually responds rapidly to calcium or vitamin D₃ therapy (Hochleithner M. 1989). In captive bred grey parrot chicks juvenile osteodystrophy is seen commonly (figures 3 & 4) with deformity of the long bones and pathological fractures identified radiographically (Harcourt-Brown N. H. 2003). Hypocalcaemia is reported in other species of psittacine birds but grey parrots appear more susceptible (McDonald L.J. 1988, Randell M.G. 1981). It has been postulated that the syndrome is due either to a primary hypoparathyroidism or a secondary nutritional hyperparathyroidism.

Captive grey parrots are commonly fed seed based diets with low calcium and vitamin D₃ contents. These diets often contain high levels of inorganic phosphate that can form phylate complexes with calcium, thereby reducing its bioavailability. It has therefore been postulated that poor diet maybe responsible for nutritional secondary hyperparathyroidism in grey parrots (Klasing K.C. 1998). Other psittacine species despite being fed the similar diets rarely develop clinical signs of hypocalcaemia (Randell M.G. 1981). Previously the reliable measurement of vitamin D₃ and parathyroid hormone concentrations has not been possible so nutritional secondary hyperparathyroidism as a cause of hypocalcaemia in the grey parrot has not been confirmed (Hochleither M. & others 1997). Primary

hypoparathyroidism has certainly not been eliminated as a cause of hypocalcaemia in the species.

Calcium metabolism in domestic poultry has been extensively researched and it has been shown that poultry must be supplied with adequate levels of dietary calcium and vitamin D₃ in order to avoid disorders of calcium metabolism (Taylor T.G. & Dacke C.G. 1984). Rickets is commonly seen in commercial poultry reared on diets containing inadequate calcium or vitamin D₃, and this is clinically very similar to juvenile osteodystrophy in grey parrots. Poultry require ultraviolet radiation (UVB spectrum 285-315nm) to convert 7-cholesterol to cholecalciferol a precursor of vitamin D₃. This provides an endogenous source of vitamin D₃ and poultry do not have a dietary requirement for vitamin D₃ if they are supplied with adequate UVB radiation (Edwards H.M. Jr. 2003). Grey parrots are indigenous to Central Africa and they live in exposed areas with low shade where they experience excellent levels of natural sunlight (May D.I. 1996). Captive grey parrots are usually kept indoors with limited access to natural ultraviolet light. Lack of adequate UVB radiation may lead to a vitamin D₃ deficiency and associated problems with calcium metabolism. It is hypothesised that grey parrots might have a higher dependency on ultraviolet light supplementation than other psittacine birds to maintain adequate vitamin D₃ metabolism. The role of UVB (285-315nm) radiation in the control of vitamin D₃ metabolism has not been researched in psittacine birds.

This 3 year study was performed on a captive population of 100 sexually mature grey parrots kept indoors in the UK with the informed consent of the owner. Two groups of 20 grey parrots were selected randomly from the main population. The 2 groups were fed diets containing different dietary concentrations of calcium and vitamin D₃ under identical ultraviolet light levels for 12 months. The birds were then exposed to artificial ultraviolet lighting (UVB 285-315nm spectrum) without dietary change for a further 12 months. Blood samples were taken to measure ionised calcium, parathyroid hormone and 25 hydroxycholecalciferol in the birds during routine annual health checks. Data from this research were used to elucidate the effects of husbandry on calcium metabolism in the grey parrot and could be used to produce reference ranges for ionised calcium, 25 hydroxycholecalciferol and parathyroid hormone. The data were compared with the same

parameters measured in a small group of wild grey parrots in Africa and a group of South American birds kept in the UK.

This study also investigated clinical cases of hypocalcaemia in adult grey parrots and juvenile osteodystrophy in young greys presented at the author's practice during the same 3 year period. Plasma ionised calcium, 25 hydroxycholecalciferol and parathyroid hormone concentrations in the hypocalcaemic birds were compared with results from the main study group. Bone densitometry was used to evaluate bone mass in both normal juvenile grey parrots and in chicks showing radiographic evidence of osteodystrophy. The histological appearance of parathyroid glands and bone of grey parrots euthanased on humane grounds with severe osteodystrophy were examined to test the hypothesis that grey parrots suffer from nutritional secondary hyperparathyroidism. These pathological samples were compared statistically with tissues from juvenile grey parrots showing no radiographic evidence of osteodystrophy.

The primary aim of this study was to investigate normal and abnormal calcium metabolism in the grey parrot and to test the hypothesis that nutritional secondary hyperparathyroidism is responsible for the high prevalence of hypocalcaemia in this species. The results of this study allow husbandry protocols designed to prevent the common clinical presentations of hypocalcaemia in the grey parrot to be proposed and the reasons these birds are more susceptible to the disease than other psittacine birds to be explored.



Figure 1. An adult grey parrot (*Psittacus e. psittacus*). This captive bred bird is a friendly, intelligent pet with an excellent talent for mimicry making it a popular pet in the UK.



Figure 2. A juvenile captive bred grey parrot. The young grey parrot is distinguished from the adult birds by the dark colouration of the iris. The iris changes colour from black to pale yellow during its first year.

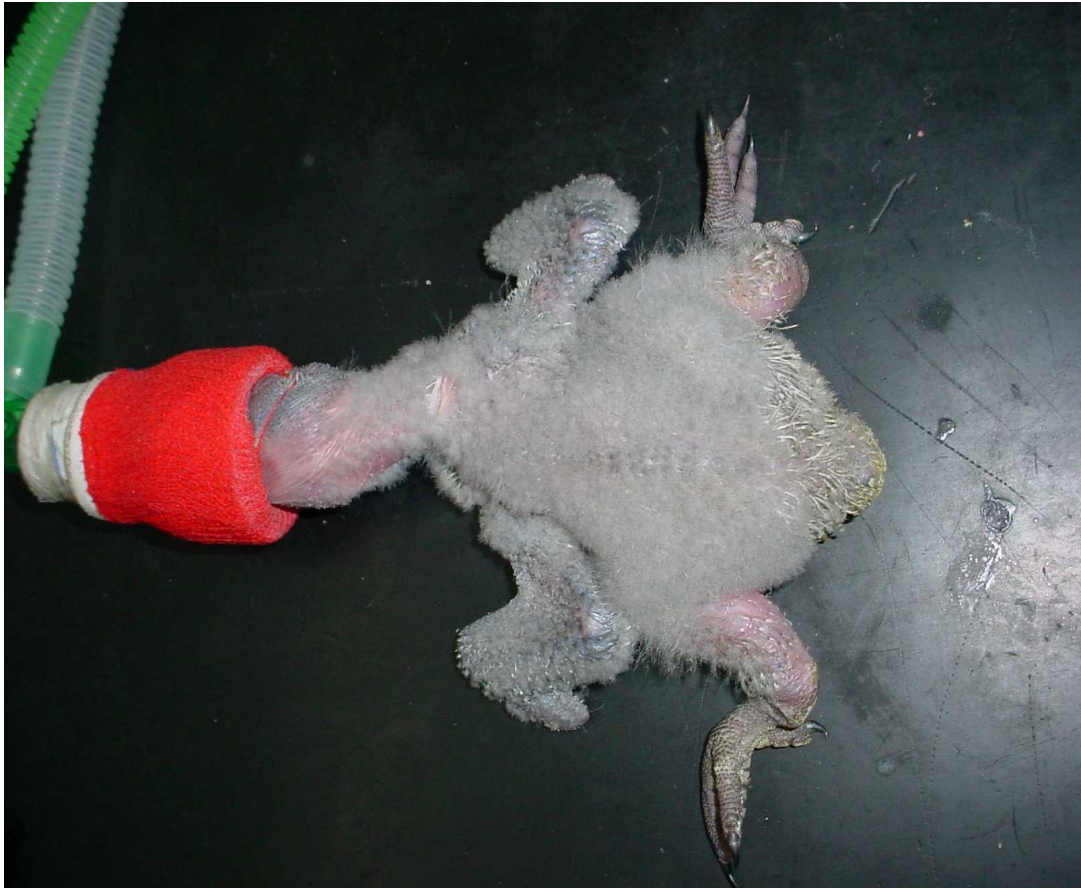

Figure 3. A 6 week old captive bred hand reared grey parrot with severe juvenile osteodystrophy. There is obvious bilateral bowing of the tibiotarsus. Radiography revealed evidence of osteodystrophy in wings, legs and spine with numerous pathological fractures. The bird was euthanased on humane grounds. The bird had been hand reared on a cereal diet with no additional calcium or vitamin D₃ supplementation.

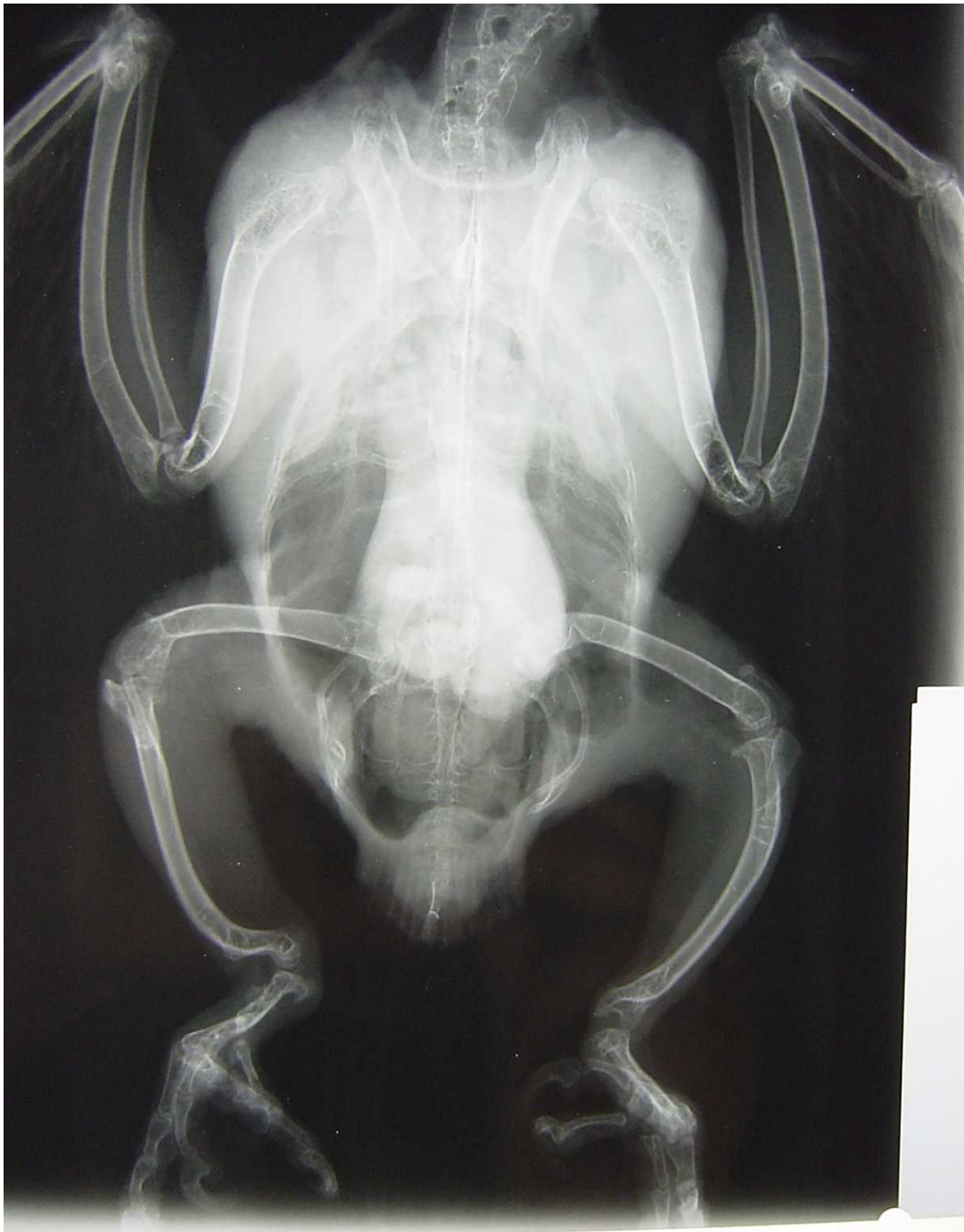

Figure 4. A dorsal-ventral radiograph of an 8 month old captive grey parrot. The radiograph indicates evidence of juvenile osteodystrophy with bowing in both tibiotarsi. There is also obvious distortion in both wings. The radiographs were taken as part of a post purchase examination and the bird was otherwise healthy.

CHAPTER 2

Literature review

2.1 Control of calcium metabolism in birds

Calcium has two important physiological roles in the bird. It provides structural strength for the avian skeleton and has a vital role in many biochemical reactions within the body via its concentration as the ionised salt in tissue fluids (Dacke C.G. 2000). Calcium exists as three fractions in avian serum: an ionised salt, calcium bound to proteins and complex calcium bound to a variety of anions (citrate, bicarbonate and phosphate). Ionised calcium, which is the physiologically active fraction of serum calcium, is essential for bone homeostasis, muscle and nerve conduction, blood coagulation, and the control of hormone secretion, particularly vitamin D₃ and parathyroid hormone. The control of calcium metabolism in birds has developed into a highly efficient homeostatic system able to respond quickly to sudden demands for calcium. This is required for the production of hard-shelled eggs and the rapid growth rate in young birds (Hurwitz S. 1989). Calcium is controlled mainly by parathyroid hormone (PTH), metabolites of vitamin D₃ and calcitonin that act on the target organs liver, kidney, gastrointestinal tract and bone in direct response to changes in serum ionised calcium concentrations (Taylor T.G.& Dacke C.G. 1984). Oestrogen and prostaglandins also have a role in calcium regulation in the bird (Dacke C.G. 2000). There are distinct differences between the mammalian and avian system. The most dramatic difference between the two phylogenetic groups is in the rate of skeletal metabolism in birds at times of demand. Domestic chickens will correct hypocalcaemic challenges within minutes whereas similarly challenged mammals respond over a period of 24 hours (Koch J. & others 1984). Egg laying hens require 10% of the total body calcium reserves for egg production in a 24 hour period (Etches R.J. 1987). The calcium required for eggshell production is obtained by increased intestinal absorption, and from the highly labile reservoir found in the medullary bone, normally visible radiographically in sexually mature female birds (figure 5). With the exception of dinosaurs the evolutionary development of

medullary bone formation appears unique to the class Aves (Schweitzer M.H. & others 2005). Approximately 60-75% of the eggshell calcium is derived from dietary sources and the remainder from medullary bone (Driggers J.C. & Comar C.L. 1949). Hens fed a calcium deficient diet will stop laying when the plasma ionised calcium concentration falls to below 1.0mmol/l (Luck M.R. & Scanes C.G. 1979). Medullary bone develops in bones with vascular bone marrow rather than those with a pneumatic function and the formation of medullary bone coincides with the maturation of ovarian follicles in laying hens. The rapid metabolic response by the avian skeleton has resulted in it becoming a common model for skeletal studies concerning the regulation of calcium (Norman A.W. 1990). Abnormalities of calcium metabolism are common in the poultry industry leading to poor production and growth defects such as tibial dyschondroplasia in broiler chickens housed indoors (Thorp B.H. 1992). The economic importance of the poultry industry has encouraged calcium metabolism to be extensively researched in production birds particularly with regard to the evaluation of dietary calcium, vitamin D₃, and importance of ultraviolet radiation (Elaroussi A. M. & others 1994, Edwards H.M. Jr. & others 1994, Aslam S.M. & others 1998). Disorders of calcium metabolism are also common in captive grey parrots with signs ranging from osteodystrophy in young birds (due in part to the greater calcium requirement in young growing birds) to hypocalcaemic convulsions in adults (Hochleither M. 1989, Hochleither M. & others 1997, Roskopf W.J. & others 1985, Harcourt-Brown N.H. 2003). Although grey parrots are considered to be especially susceptible to disorders of calcium metabolism, problems have been reported in a variety of captive psittacine species (Arnold S.A. & others 1973, Roskopf W.J. & others 1981). Husbandry requirements, with respect to calcium metabolism, have been poorly researched in captive birds to date and much of our present knowledge is extrapolated from work with poultry and wild birds.

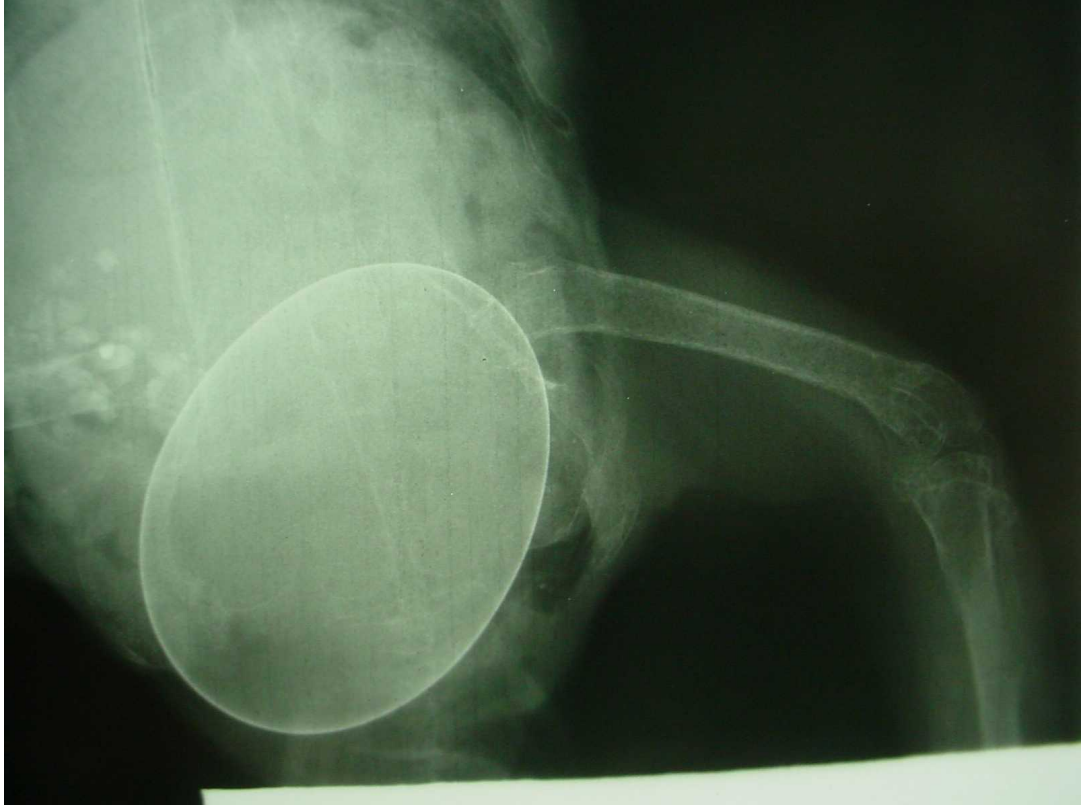


Figure 5. A dorsal-ventral radiograph of an egg bound grey parrot. The film demonstrates the presence of medullary bone in mature female birds. The characteristic fluffy appearance of medullary bone can be visualised in the medullary cavity of the femur. The bird was diagnosed with egg peritonitis and a salpingohysterectomy was performed to remove the egg.

2.2 Vitamin D and calcium metabolism

Vitamin D₃ metabolism in poultry has been extensively researched (Taylor T.G. & Dacke C.G. 1984, Norman A.W. 1987, Hurwitz S. 1989, Kumar R. 1984, Soares J.H. Jr. 1984).

The importance of the vitamin's role in bone development and the requirement of ultraviolet light for its metabolism has been overcome by the commercial availability of dietary vitamin D₃ which is essential for the indoor production of poultry (Edwards H.M. & others 1994).

The main role of vitamin D₃ is in the control of bone metabolism by both regulating mineral absorption and controlling the differentiation of its cellular elements (Norman A.W. & Hurwitz S. 1993). Recent studies have found that vitamin D₃ also has profound effects on the immune system, skin and cancer cells (Abe E. & others 1983, Tsoukas C.D. & others 1984, Holick M.F. & others 1987). For example in broiler chicks vitamin D₃ deficiency causes depression of the cellular immune response (Aslam S.M. & others 1998). Vitamin D₃ (cholecalciferol) is the form of vitamin found throughout the animal kingdom but only very rarely in plants (Boland R.L.B. 1986). It is naturally found in fish, eggs, meat and milk. In plants, vitamin D occurs as vitamin D₂ (ergocalciferol), which most mammals can utilise (except some New World primates) as well as vitamin D₃. Birds cannot utilise vitamin D₂ (Massengale O.N. & Nussmeier M. 1930). This is due to increased renal clearance of vitamin D₂ rather than poor intestinal absorption (Hoy D.A. & others 1988, Hurwitz S. & others 1967). In addition, the binding of vitamin D₂ to plasma proteins in birds is less efficient than in mammals (Deluca H.F. & others 1988).

Birds acquire vitamin D₃ from a combination of endogenous synthesis and dietary supply. The skin has been established as the organ for vitamin D₃ production as in mammals. Birds secrete 7-dehydrocholesterol onto featherless areas of skin (Koch E.M. & Koch F.C. 1941). Recently it has been shown that there is thirty times more 7-dehydrocholesterol on the featherless leg skin than the back skin indicating the importance of this area for vitamin D₃ metabolism (Tian X.Q. & others 1994a). 7-dehydrocholesterol is converted to cholecalciferol by an ultraviolet light (285-315nm wavelength) dependent isomerisation reaction. Cholecalciferol is a sterol prohormone which undergoes a temperature dependent isomerisation reaction to form vitamin D₃ (Holick M.F. 1989, Tian X.Q. & others 1993)). After translocation into the circulation vitamin D₃ is transported bound to a specific globulin

binding protein (Bouillon R. & others 1980). There is a time delay between vitamin D₃ production on the skin and its translocation into the circulation (Tian X.Q. & others 1994b). Cholecalciferol can be stored in adipose tissue but to be physiologically active it must be metabolised by a 2 stage hydroxylation process (Holick M.F. 1995).

Cholecalciferol is initially metabolised to 25 hydroxycholecalciferol in the liver (Blunt J.W. & others 1968); 25 hydroxycholecalciferol is transported to the kidney via carrier proteins and converted to either 1, 25 dihydroxycholecalciferol or 24, 25 dihydroxycholecalciferol, the normal active metabolites of cholecalciferol in the domestic fowl. Cholecalciferol is classified as a fat soluble vitamin but 1,25 dihydroxycholecalciferol has been reclassified as a steroid hormone after the discovery of feedback pathways between calcium and the synthesis of vitamin D₃. The most significant active metabolite of vitamin D₃ in domestic chickens is 1, 25 dihydroxycholecalciferol which controls both bone development and intestinal calcium absorption (Brommage R. & Deluca H.F. 1985). This metabolite has a short life, being rapidly degraded by its target organs (Holick M.F. 1999). 24, 25 dihydroxycholecalciferol is also thought to have an active role in poultry (Henry H.L. & Norman A.W. 1978, Ornoy A. & others 1978) although it is not known to have any significant activity in mammals. Specific receptors for 24,25 dihydroxycholecalciferol have been found in chondrocytes and parathyroid glands of poultry. The metabolite modulates the action of both 1, 25 dihydroxycholecalciferol and parathyroid hormone on intestinal calcium transport (Nemere I. 1999, Kriajev L. & Edelstein S. 1994). Twenty-eight other metabolites of vitamin D₃ have been isolated in poultry although their importance is not known at the present time (Norman A.W., 1987). In rats, chickens and quail these additional metabolites have a synergistic effect on calcium absorption and bone formation (Rambeck W.A. & others 1988).

The production of 25 hydroxycholecalciferol is rapid and has no feedback mechanism to calcium metabolism. It is controlled purely by product inhibition (Omdahl J.L. & Deluca H.F. 1973). In practice, blood concentrations of 25 hydroxycholecalciferol can vary depending on recent dietary intake (Johnson M.S. & Ivey E.S. 2002). The synthesis of 1, 25 dihydroxycholecalciferol is also rapid, but this conversion is tightly regulated by many factors, in particular parathyroid hormone (PTH), in response to the calcium status of the

bird (Fraser D.R. & Kodiek E. 1973). Parathyroid hormone controls the production of 1, 25 dihydroxycholecalciferol by regulating the enzyme, 25 hydroxycholecalciferol-1-hydroxylase, responsible for the second hydroxylation step in the kidney (Bar A. & others 1980, Suda T. & others 1994). This action of PTH in the kidney is known to be mediated by cAMP (Henry H.L. 1985). Another important part of the regulation is 1,25 dihydroxycholecalciferol feedback on itself within the kidney abolishing 25 hydroxycholecalciferol-1-hydroxylase activity (Colston K.W. & others 1977, Spanos E. & others 1978).

Metabolism of vitamin D₃ leads to a lag phase of several hours between supplementing vitamin D₃ deficient animals with the hormone and the resulting increased calcium absorption. Vitamin D₃, therefore, acts as a constraint preventing large fluctuation in plasma calcium concentrations compared with parathyroid hormone, which has a more immediate action. There are no known cases of vitamin D₃ intoxicification resulting from excessive exposure to ultraviolet radiation. This is probably due to the UVB dependent photoisomerisation of previtamin D₃ to lumisterol and tachysterol, which are inert. This process is reversible and these photoisomers can act as a store for cholecalciferol in the skin (Holick M.F. 1994). Excess UVB can also degrade cholecalciferol to inert compounds (such as prasterol I, suprasterol II and 5, 6 transvitamin D₃) that are also inert (Ferguson G.W. & others 2003). In man latitude, time of day and season of year can dramatically affect the production of cholecalciferol in the skin (Holick M.F. 1999). It has been demonstrated that different domestic animals convert 7-dehydrocholesterol to cholecalciferol with varying efficiency (Horst R.L. & others 1982). The photobiology of vitamin D₃ is a vital process in both mammals and birds. The wide spread application of sunscreens to prevent skin cancer has been shown to reduce the cutaneous production of vitamin D₃ by 95% in man (Holick M.F. 1994). Failure to provide adequate UVB light for indoor poultry produces signs of vitamin D₃ deficiency. Studies have been conducted in order to demonstrate the requirement for dietary cholecalciferol in poultry not provided with ultraviolet light (Edwards H.M. Jr. & others 1994). If ultraviolet light was excluded and dietary cholecalciferol concentrations fell below 400 IU/kg, signs of rickets were seen with concurrent low plasma ionised calcium concentrations.

Failure of vitamin D₃ metabolism can occur in animals with liver or kidney disease. In man it has been demonstrated that over 90% of hepatic function must be lost before production of 25 hydroxycholecalciferol is affected. Renal disease is more significant. The loss of renal mass causes a reduction of production of 1,25 dihydroxycholecalciferol from the proximal convoluted tubular cells (Holick M.F. 1999). Increased excretion of 1,25 dihydroxycholecalciferol occurs in cases of protein losing nephropathy.

Absorption of dietary vitamin D₃, which occurs in the upper small intestine, is 60-70% efficient in both chickens and turkeys (Bar A. & others 1980). Dietary deficiency of vitamin D₃ leads to a decrease in circulatory calcium, 25 hydroxycholecalciferol and decreased eggshell specific gravity (Tsang C.P. & Grunder A.A. 1993). Excessive dietary vitamin D₃ causes disruptions in calcium and phosphorus metabolism in poultry usually resulting in profound hypercalcaemia with associated soft tissue calcification (Soares J.H. & others 1983, Brue R.N. 1994, Soares J.H. 1995). Renal calcification is fatal due to kidney failure. Vitamin D₃ toxicity may be diagnosed by the demonstration of an elevated serum 25 hydroxycholecalciferol concentration (Holick M.F. 1999). The relative toxicity of each vitamin D₃ metabolite is proportional to its bioactivity. For this reason cholecalciferol is normally used for supplementing avian diets in preference to the active metabolites. The susceptibility to vitamin D₃ toxicity varies between species. Toxicity has been shown to occur at lower levels of dietary vitamin D₃ in several macaw groups compared with other avian species (Klasing K.C. 1998). Growing poultry chicks have been shown to tolerate high levels of dietary vitamin D₃ (Baker D.H. & others 1998). In commercial poultry units there is, usually a compromise between dietary vitamin D₃ (on the basis of economy and toxicity) and ultraviolet light supplementation provided for adequate vitamin D₃ metabolism (Klasing K.C. 1998).

The function of vitamin D₃ is reliant on the presence of normal vitamin D₃ receptors. In humans vitamin D₃ dependent rickets can be caused by abnormalities of the vitamin D₃ receptors (Feldman D. & others 1990). Receptors for 1, 25 dihydroxycholecalciferol have been purified from the expected target organs of calcium metabolism: osteoblasts, osteocytes, intestinal epithelium, renal epithelium, parathyroid gland and shell gland (Haussler M.R. 1986, Iwamoto M. & others 1989, Boivin G. & others 1987, Coty W.A. 1980,

Takahashi N. & others 1980, Lu Z. & others 2000). The receptors have also been found in 23 tissues in the hen including skin, skeletal muscle, gonads, pancreas, thymus, lymphocytes and pituitary gland (Haussler M.R. 1986, Reichel H. & others 1989, Dokoh S. & others, 1983). The gene sequence of the avian vitamin D₃ receptor differs from the mammalian receptor although the hormone binding domain is conserved (Elaroussi M.A. & others 1994). The bird is therefore considered a valid model for vitamin D₃ research in mammals including man (Norman A.W. 1990)

2.3 Metabolic functions of vitamin D in birds

2.3.1 Effects on mineral absorption

In a growing chicken 70% of calcium absorption is vitamin D₃ dependent compared with 10% in a growing rat (Hurwitz S. & others 1969). It is postulated that vitamin D₃ regulates calcium absorption across the intestinal wall by inducing the formation of the carrier protein calbindin D_{28k} (Wasserman R.H. & Taylor A.N. 1966, Theofan G. & others 1986). Injecting a vitamin D₃ deficient chicken with 1,25 dihydroxycholecalciferol produces a detectable increase in calbindin D_{28k} concentrations in the intestinal epithelium (Mayel-Afshar S. & others 1988). Calbindin D_{28k} has been found in 8 avian tissues (Nemere I. & Norman A.W. 1991). These include those responsible for calcium transport such as intestine, kidney, oviduct and shell gland (Jand S.S. & others 1981, Hall A.K. & Norman A.W. 1990). The presence of this protein reflects the ability of the organs to absorb or excrete calcium (Rosenburg R. & others 1986). The action of calbindin D_{28k} in calcium transport is controversial but it is known to facilitate transepithelial calcium transport and protect cells from excessively high calcium concentrations via a buffering effect (Nemere I. & Norman A.W. 1991). It is found in greater concentration in the distal oviduct and shell gland than the proximal oviduct, correlating with known sites of eggshell formation (Wasserman R.H. & others 1991). Vitamin D₃ has been shown to have a direct effect on intestinal epithelial cell differentiation. Vitamin D₃ deficient animals have shorter intestinal villi, thereby reducing the surface area available for calcium absorption. Supplementation with 1, 25 dihydroxycholecalciferol has been shown to restore normal villus length (Suda T. & others

1990). Vitamin D₃ also increases the intestinal absorption of phosphorus. This action is considered independent of the vitamin D₃ action on calcium absorption (Wasserman R.H. & Taylor A.N. 1973). The rapid effects of 1,25 dihydroxycholecalciferol on calcium transport in the intestine is partially modulated by 24,25 dihydroxycholecalciferol (Nemere I. 1999).

2.3.2 Effects on bone

Longitudinal bone growth in birds is initiated by cartilaginous cells rather than bone tissue (Hurwitz S. & Pines M. 1991). For normal cartilage and bone growth in poultry both 1,25 dihydroxycholecalciferol and 24,25 dihydroxycholecalciferol have been shown to be essential (Ornoy A. & others 1978). They exert their effect by enhancing the differentiation of chondrocyte and bone cells. Although the cartilaginous tissue in the growth plate is lost towards the end of longitudinal bone growth remodelling of bone is continuous throughout life as in mammals. The action of 1, 25 dihydroxycholecalciferol promotes bone formation by inducing the synthesis of osteocalcin. This protein is involved in the mineral dynamics of bone (Hauschka P.V. & others 1989) and its presence in the circulation reflects increased osteoblast activity (Nys Y. 1993). Vitamin D₃ has been shown to stimulate bone resorption indirectly by promoting osteoclast formation and activity (Tanaka Y. & Deluca H.F. 1971, McSheehy P.M.J. & Chambers T.J. 1986). The process of bone calcification is related to the presence of cholecalciferol (Dickson I.R. & Kodicek E. 1979). As previously discussed in egg laying birds 30-40% of the calcium required for eggshell formation is acquired from medullary bone. The homeostatic control of medullary bone has been shown to involve oestrogen activity and 1, 25 dihydroxycholecalciferol (Takahashi N. & others 1983). The plasma concentration of 1,25 dihydroxycholecalciferol is highest immediately before and during the shell calcification phase of the egg laying cycle (Castillo L. & others 1979).

2.3.3 Effects on chick embryo development

Vitamin D₃ is required for normal hatching of chicken eggs (Henry H.L. & Norman A.W. 1978). Although the developing embryo can utilise 1,25 dihydroxycholecalciferol hens fed only this form of vitamin D₃ show poor hatchability of the eggs due to abnormal calcification of the embryonic beak (Soares J.H. Jr 1984). This is caused by inadequate transport of

1,25 dihydroxycholecalciferol into the egg compared with 25 hydroxycholecalciferol. Both 1, 25 dihydroxycholecalciferol and 24, 25 dihydroxycholecalciferol play an important role in the control of calcium transport from yolk to embryo. Calcium is obtained from the eggshell from day 10 (Johnston P.M. & Comar C.L. 1955). Transport of calcium across the embryonic intestine and yolk sac membrane is facilitated by vitamin D₃ metabolites (Corradino R.A. 1985, Clark N.B. & others 1989). Vitamin D₃ deficient chicken embryos are unable to complete the prehatching positional changes required for pulmonary respiration. In the same embryos bone and muscle weights are lower than would be expected because of increased parathyroid gland activity (Narbaitz R. & Tsang C.P. 1989). The changes can be reversed with intra-embryonic vitamin D₃ injections. There is a strong correlation between the dietary cholecalciferol supplied to poultry and both the cholecalciferol ($r^2=0.995$) and 25 hydroxycholecalciferol ($r^2=0.941$) contents of egg yolk (Mattila P. & others 1999, Mattila P. & others 2003). This is important, as eggs are presently the major human dietary source of dietary vitamin D₃.

2.4 Parathyroid hormone (PTH)

Parathyroid hormone (PTH) secreted by chief cells in the parathyroid gland has a vital role in calcium homeostasis in egg laying birds (Kenny A.D. & Dacke C.G. 1974, Dacke C.G. 1979). The avian chief cells have a low granular content, correlating with the low level of circulating PTH compared with mammals (Kenny A.D. 1986). As in mammals, PTH has a hypercalcaemic action, which maintains a normal blood calcium concentration despite fluctuations in dietary calcium, reproductive state, bone metabolism and renal function. If a parathyroidectomy is performed in quail, the birds suffer severe hypocalcaemia (Clarke N.B. & Wideman R.F. 1977). PTH secretion is mainly regulated by the serum ionised calcium concentration although 1,25 dihydroxycholecalciferol is also involved (Juppner H. & others 1999). Birds appear more sensitive to PTH than mammals reacting to intravenous injections of the hormone within minutes with a rise in blood ionised calcium concentrations (Candlish J.K. & Taylor T.G. 1970). In mammals the hypercalcaemic

response to PTH may take several hours. This suggests that PTH is probably at least partially responsible for the speed of calcium metabolism in birds compared with mammals.

The main target organs of PTH in birds are the kidney and the bone (Dacke C.G. 2000). PTH directly stimulates osteoclasts to resorb bone. PTH binds to osteoclasts and increases bone resorption by stimulating their metabolic activity and division. PTH also actively stimulates osteoblast activity, and it is thought that PTH-stimulated osteoblasts regulate osteoclast activity, thereby providing the precise control system necessary in avian skeletal metabolism (Bentley P.J. 1998). The action of PTH is also concentrated on osteoclasts in medullary bone in laying chickens (Bannister D.W. & Candlish J.K. 1973).

Parathyroid hormone also has direct influence on both calcium and phosphorus excretion in the bird by means of PTH receptors on the renal plasma membranes (Nissenson R.A. & Arnaud C.D. 1979, Bar A & Hurwitz S 1980). The normal avian kidney reabsorbs more than 98% of filtered calcium and excretes approximately 60% of filtered phosphate in the urine (Wideman R.F. 1987). Calcium excretion is increased and phosphorus decreased following parathyroidectomy. These changes can be reversed by injections of PTH. The transport of calcium and phosphorus in the kidney is dissociated allowing appropriate blood concentrations of either mineral to be maintained despite severe dietary stresses (Wideman R.F. 1987). Parathyroid hormone has also been demonstrated to be hypomagnesiuric in the bird due to its effects on the kidney (Wideman R.F. Jr & Youtz S.L. 1985). In addition PTH has a significant role in regulating intestinal phosphate absorption in chickens (Nemere I. 1996).

Parathyroid glands enlarge and contain increased secretory granules during reproductive activity (Nevalainen T. 1969). During egg calcification serum PTH levels inversely correlate with ionised calcium concentrations in chickens (Van de Velde J.P. & others 1984). The mechanism for this involves the expression of a calcium-sensing receptor gene by the parathyroid gland chief cells. In contrast to mammals the calcium receptor gene expression is inversely associated with ionised calcium concentrations (Yarden N. & others 2000). The mobilisation of calcium for eggshell formation is considered to be under parathyroid control (Singh R. & others 1986). Hypertrophy of the parathyroid gland occurs in chickens fed calcium deficient diets (Taylor T.G. 1971). Similar pathological changes have been

demonstrated in parakeets suffering with nutritional secondary hyperparathyroidism when fed a seed diet (Arnold S.A. & others 1973).

Parathyroid hormone is a single chain polypeptide that comprises of 84 amino acids in all known mammalian analogues. The peptide has been extracted from the parathyroid gland of chickens fed a vitamin D₃ deficient diet using gel filtration and high performance liquid chromatography (Pines M. & others 1984). It has been demonstrated that in chickens parathyroid hormone consists of 88 amino acids with significant gene deletions and insertions compared with the mammalian homolog although its molecular weight is similar (Khosla S. & others 1988, Russell J. & Sherwood L.M. 1989, Lim S.K. & others 1991). The avian peptide has higher concentrations of glycine but is reduced in the basic amino acids (Pines M. & others 1984). The greatest similarity is found in the biologically active N-terminal 1-34 segment of the peptide chain, which is also responsible for much of the activity of the hormone (Russell J. & Sherwood L.M. 1989). The response of the avian renal system to bovine PTH (1-84), human PTH (1-34) and bovine PTH (1-34) demonstrated a more phosphaturic response with the 1-34 analogues (Wideman R.F Jr. & Youtz S.L. 1985). In grey parrots previous studies were unable to accurately analyse PTH using mammalian assays (Hochleither M. & others 1997). Despite this it is always useful to assay PTH in a hypocalcaemic subject to distinguish between hyperparathyroidism and hypoparathyroidism.

Parathyroid hormone-related protein (PTHrP) is a second member of the PTH family originally discovered as a cause of hypercalcaemia in malignancy in man. PTHrP has three isoforms of 139, 141 and 173 amino acids all with identical sequences through to amino acid 139. The hormone has distinct structural and functional relationships with PTH suggesting a common ancestral gene. There is distinct homology between the structure of mammalian and avian PTHrP in the 1-34 segment with PTH. Parathyroid hormone and PTHrP can share a common receptor. Many tissues in the chicken embryo contain levels of PTHrP (Schermer D.T. & others 1991). As in man, PTHrP is felt to play many regulatory and developmental roles in a variety of tissues. Concentrations of PTHrP have been shown to rise in the shell gland of the chicken during the calcification cycle affecting smooth muscle activity in the gland. Levels of PTHrP return to normal once the egg has been laid

(Miller S.C. 1977, Thiede M.A. & others 1990). PTHrP has been shown to have effects on bone resorption in the chicken embryo.

2.5 Calcitonin

The ultimobranchial gland in birds and other sub mammals produces calcitonin. It is a 32 chain amino acid hormone which exerts an essentially hypocalcaemic effect in response to rising serum ionised calcium levels by reducing osteoclast activity (Dacke C.G. 2000). The levels of circulating calcitonin in all sub mammals are high and readily detectable compared with PTH. There are considerable structural differences between species with salmon only sharing 9 common amino acids with mammalian calcitonin (Deftos L.J. & others 1999). Serum concentrations of calcitonin are best-measured using radioimmunoassay in man. There is poor cross-reactivity between antibodies of calcitonin among species and calcitonin radioimmunoassays are not available for poultry. The bioactivity of calcitonin also varies between phylogenetic groups with fish calcitonin exhibiting the most potent effect. In the bird calcitonin levels increase following injections of calcium. There is a direct correlation between calcitonin levels and dietary calcium concentrations (and hence serum calcium levels). Although calcitonin has been shown in man to exert its hypocalcaemic effects mainly by inhibiting bone osteoclastic bone resorption its biological action in the bird remains surprisingly unclear despite the high circulating levels of the hormone in this group. In chickens fed a calcium deficient diet the circulating concentration of calcitonin is undetectable and reduced numbers of secretory cells can be demonstrated in the ultimobranchial glands (Eliam-Cisse M.C. & others 1993). Metabolic disorders involving abnormal concentrations of calcitonin appear to be rare in birds.

2.6 Oestrogen

The effects of oestrogen on calcium metabolism have been researched in poultry (Sommerville B.A. & others 1977). Oestrogens promote the formation of the vitellogenins in the liver. These are lipoproteins, which are incorporated into the egg yolk. They bind calcium and their production is followed by a rise in serum calcium levels. The response to oestrogen is not linear in the growing chick (Sommerville B.A. & others 1989). This

oestrogen controlled hypercalcaemic effect is not seen in mammals and is felt to be due to the need to produce large calcified eggs requiring a rapidly mobilised source of calcium. Oestrogens also influence the mobilisation of medullary bone during the egg laying cycle (and also during the nocturnal fast). The effect of oestrogen on avian medullary bone is a large research area due to the importance of oestrogen in maintaining bone mass in postmenopausal women (Eastwell R. 1999). In female birds oestrogen increases calcium absorption from the intestine by increasing the activity of alkaline phosphatase. This function is dependent on the action of vitamin D₃ (Qin X. & others 1993). If laying hens are fed a calcium or vitamin D₃ deficient diet the metabolic pathways of oestrogen are affected leading to oestrogen deficiency (Tsang C.P. & others 1988). Oestrogen has been demonstrated to have the same effect on serum ionised calcium concentrations in fresh water turtles (Clarke N.B. 1967).

2.7 Prostaglandins

Prostaglandins were first implicated in poultry bone metabolism in 1970 (Klein D.C. & Raisz L.G. 1970). They act locally, in the bone, being produced by chondrocytes, osteoblasts, monocytes, macrophages and lymphocytes. The prostaglandins of the E series have the greatest activity in poultry bone. PGE₂ is a powerful facilitator of bone resorption with similar hypercalcaemic effects to PTH and vitamin D₃ metabolites. The osteoclast appears to be the main site of action for prostaglandin although in vitro studies have demonstrated effects on osteoblasts too. Injections of prostaglandin into chickens will produce hypercalcaemia and the use of prostaglandin antagonists will produce hypocalcaemia (Kirby G.C. & Dacke C.G. 1983, Dacke C.G. & Kenny A.D. 1982). PGE₁ and PGE₂ also both stimulate bone formation and proliferation and differentiation of osteoprogenitor cells. Furthermore it has been demonstrated that prostaglandins can either stimulate or inhibit the conversion of 25 hydroxycholecalciferol to the active metabolite 1,25 dihydroxycholecalciferol in the renal tubule (Wark J.D. & others 1984). Cytokines have also been implicated in local bone metabolism regulation influencing resorptive and osteogenic activities.

2.8 Investigating abnormalities of calcium metabolism

There is a relationship between calcium and phosphate homeostasis controlled by one endocrine axis involving predominately parathyroid hormone, 1,25-dihydroxycholecalciferol and calcitonin. Disorders of calcium metabolism are normally investigated by measuring ionised calcium, parathyroid hormone and 25 hydroxycholecalciferol. In addition it would be useful to measure phosphate and magnesium.

2.8.1 Calcium

The measurement of serum ionised calcium provides a precise estimate of an individual's calcium status especially in the diseased patient (Portale A.A. 1999,Torrance A.G. 1995). Unfortunately the majority of veterinary pathology laboratories only report a total calcium value, measured by spectrophotometer, which reflects the total combined levels of ionised calcium, protein bound calcium and complexed calcium (Bush B.M. 1991). This can lead to misinterpretation of calcium results in birds, as any change in protein bound calcium is not thought to have any pathophysiological significance (Stanford M.D. 2003,Stanford M.D. 2005,Torrance A.G. 1995). Measurement of total calcium in an avian patient with abnormal protein levels or acid-base abnormalities would not truly reflect the calcium status of the animal as any changes in serum albumin values will affect the total calcium concentration, leading to an imprecise result. For example, in laying female birds, serum albumin levels may rise by up to 100% to provide albumin for yolk and albumen production (Williams T.D. & others 2001). A blood sample analysed at this time would show an inflated total calcium concentration due to an increased protein bound calcium fraction whilst the ionised calcium level would not be affected. The binding reaction between the calcium ion and albumin is strongly pH dependent so acid base imbalances will also affect ionised calcium levels. Therefore a patient with metabolic acidosis would be expected to show an ionised hypercalcaemia due to decreased protein binding. With an alkalotic patient an ionised hypocalcaemia would occur as the protein binding reaction increases. In mammals positive correlations have been found between albumin and total calcium levels so formulae have been developed which "correct" total calcium levels for fluctuations in albumin levels. Research has suggested these corrected estimates of free calcium are inaccurate in 20-

30% of cases in mammals (Ladenson J.H. & others 1978). The relationship between total calcium and albumin diminishes with the severity of the disease in mammals so the use of correction formulae is now thought to be less useful. In conclusion the measurement of ionised calcium is to be preferred in both mammals and birds wherever possible.

Previous research by J.T. Lumeij (1990) in psittacine birds found a positive correlation between albumin and total calcium in grey parrots, but not in amazons (*Amazona* spp). Recent work with healthy grey parrots found no significant positive correlation between albumin and total calcium concentrations (Stanford M.D. 2003a). A laboratory reference range for ionised calcium in healthy grey parrots was found to be 0.96-1.22mmol/l (Stanford M.D. 2003a). In peregrine falcons (*Falco peregrinus*) a positive correlation was found between albumin and total calcium (Lumeij J.T. & others 1993). A group of 68 healthy thick-billed parrots (*Rhynchopsitta pachyrhyncha*) were analysed for ionised calcium, total calcium, parathyroid hormone and vitamin D₃ in a zoo collection (Howard J.M. & others 2004). This study demonstrated a significant linear relationship between albumin and total calcium concentrations. The thick-billed parrots had lower ionised calcium concentrations than those reported for other birds (0.82-1.13 mmol/l).

The methodology employed by analysers to assay ionised calcium is based on the ion selective electrode (ISE) measurement principle to precisely determine individual ion values. Portable analysers using ion selective electrodes are increasingly available for use in veterinary clinics such as the I-STAT system (I-STAT Corporation, New Jersey, USA). Blood samples for ionised calcium assays should be analysed as soon as possible after venepuncture as changes in the pH of the sample will affect the accuracy of the ionised calcium levels. It is important to chill the samples immediately to reduce glycolysis by the red blood cells which continue to produce lactic acid as a by product reducing the pH of the sample. The sample will lose carbon dioxide if it is exposed to room air increasing the pH of the sample and subsequently reducing the ionised calcium measured. Despite this a study in dogs suggests that samples will not be adversely affected if not assayed for up to 72 hours so it is possible to use external laboratories (Schenck P.A. & others 1995). In grey parrots delaying samples analysis for up to 72 hours has not been found to significantly affect ionised calcium assays (Stanford M.D. 2003a). Heparin binds calcium. This is a

potential problem with analysing bird samples, as heparin is the normal anticoagulant used. Each unit of heparin has been demonstrated to bind 0.001mmol/l of ionised calcium (Fraser D. & others 1994). It is therefore important to achieve the correct ratio of heparin anticoagulant to blood volume by filling the blood sample tubes with the required amount.

2.8.2 Vitamin D₃

Radioimmunoassays (RIAs) are used to detect blood concentrations of 25 hydroxycholecalciferol and 1,25 dihydroxycholecalciferol in both man and animals (Hollis B.W. & others 1993, Hollis B.W. & others 1995, Gray T.K. & others 1981, Burgos-Trinidad M. & others 1990). The metabolites of vitamin D₃ are structurally identical across all species so human assays for 1,25 dihydroxycholecalciferol and 25 hydroxycholecalciferol can be used in birds. The measurement of 25 hydroxycholecalciferol is considered the best assessment of vitamin D₃ status in an individual as it has a longer half-life than other vitamin D₃ metabolites (Hollis B.W. & others 1999). The half-life of 25 hydroxycholecalciferol is around 3 weeks compared with only 4 to 6 hours for 1,25 dihydroxycholecalciferol so measurement of serum concentrations of 1,25 dihydroxycholecalciferol only indicates recent exposure to UVB light or oral supplementation (Ullrey D.E. & Bernard J.B. 1999). The concentration of 25 hydroxycholecalciferol correlates well with dietary vitamin D₃ intake or exposure to UVB light (Soares J.H. Jr. & others 1995). For this reason the assay of 25 hydroxycholecalciferol has traditionally been used in poultry experiments to assess vitamin D₃ status of the birds. In poultry normal ranges of 25 hydroxycholecalciferol are available for diets containing different concentrations of cholecalciferol (Goff J.P. & Horst R.L. 1995). There are assays available for the other metabolites of vitamin D₃ and it is important to ensure that any assay has been optimised for the metabolite of interest. Until recently RIA assays were the only commercial assays available for both 25 hydroxycholecalciferol and 1, 25 hydroxycholecalciferol. Recently enzyme linked immune absorbent assays for 25 hydroxycholecalciferol have been developed with the advantages of both convenience and economy. This assay has been shown to correlate well with the RIA assays. This has allowed research to be carried out economically in species other than poultry. A wide range

of 25 hydroxycholecalciferol concentrations was demonstrated in a group of wild iguanas (*Iguana iguana*) receiving different concentrations of UVB light (Mitchell M. 2002). In the laying hen, 25 hydroxycholecalciferol is not expected to fall below 26nmol/l and would normally be expected to be above 50nmol/l (Dacke C.G. 2000). In a study performed on seed fed grey parrots 18 of the 34 birds assayed for 25 hydroxycholecalciferol had concentrations below 50nmol/l (Stanford M.D. 2002b). Vitamin D₃ results need to be interpreted in context of the diet and the levels of UVB light received by the individual. Sample handling for vitamin D₃ assays is not critical and assays are available for both plasma and serum samples. There is no requirement for freezing samples prior to analysis, as the vitamin is stable at room temperature. Repeated freeze-thaw cycles of the sample should be avoided, however, as the hormone will denature.

2.8.3 Parathyroid hormone

Hypoparathyroidism or hyperparathyroidism can be diagnosed from a combination of serum ionised calcium concentrations and parathyroid histopathology but direct measurement of parathyroid hormone is preferable. Parathyroid hormone assays are used to differentiate between hypercalcaemia caused by primary hyperparathyroidism and non-parathyroid aetiologies such as malignancy.

Parathyroid hormone circulates as a mixture of intact hormone and inactive mid-region and carboxyl terminal fragments. These fragments have long half-lives and interfere with intact parathyroid hormone assays so the majority of human assays involve a 2-site RIA (Blind E. & Gagel R.F. 1999). Most human assays concentrate on the mid and terminal segments of the PTH molecule due to the very short half-life of the biologically active 1-34N sections. Unfortunately correlation in structure between the poultry and mammalian PTH molecule is very poor in the middle and terminal sections so PTH assays have traditionally been difficult in birds. The avian and mammalian PTH molecule has greatest homology in the biological active 1-34N regions. The gene structure of grey parrot PTH is undetermined. A PTH 1-34N assay has been used in grey parrots with consistent results although the test has not been validated for birds (Stanford M.D. 2002a, Stanford M.D. 2005).

Parathyroid hormone is extremely labile and any assay requires exacting sample handling to produce good results (Barber P.J. & others 1993, Torrance A.G. & Nachreiner R. 1990).

The hormone is labile at greater than 20°C so it should be analysed immediately following venepuncture or the sample rapidly frozen to -70°C. Repeated freeze-thaw cycles will also denature the hormone. Proteolytic enzymes present in serum and plasma affect parathyroid hormone and it is apparently more stable if blood is taken into sample tubes containing EDTA or protease inhibitors such as aprotinin.

2.9 The effects of ultraviolet radiation on vitamin D metabolism

2.9.1 Introduction

There are three ultraviolet wavelengths recognised: UVA (315-400nm), UVB (290-315nm) and UVC (100-280nm). Although the spectrum of radiation from the sun reaching earth's atmosphere ranges from 100nm-3200nm, wavelengths shorter than 290nm are absorbed by the ozone layer thus removing all UVC radiation (Frederick J.E. & others 1989). Both UVA and UVB are responsible for skin erythema and the production of the skin tan but only UVB is associated with the photobiology of vitamin D₃. The Ultraviolet Index (UVI) is an internationally recognised unit less system of measuring ultraviolet radiation. Latitude influences UVB exposure; radiation has to travel through an increased thickness of atmosphere before reaching the earth's surface the further one progresses from the equator. For example UV radiation levels are significantly lower in the UK than at the equator. Exposure to UVB also varies over the course of the year in the UK due to the varying solar angle. In the UK an individual would receive the maximum concentration of UVB between 12.00-14.00hrs when the sun is at its highest in the sky. The behaviour of reptiles has been studied demonstrating that basking behaviour is adjusted depending on the vitamin D₃ content of the diet (Ferguson G.W. & others 2003).

2.9.2 Relationship between ultraviolet radiation and endogenous vitamin D₃ synthesis

The ultraviolet light required for endogenous vitamin D₃ synthesis can either be supplied naturally from full spectrum sunlight or using artificial lamps manufactured to provide UVB radiation. Exposure to direct unfiltered sunlight is the optimal way to provide UVB light

depending on the local UVI (Adkins E. & others 2003). The conversion of previtamin D₃ to vitamin D₃ in the skin is known to be temperature dependent (Tian X.Q. & others 1993). The temperature received by a grey parrot in captivity in the UK would be less than its wild counterparts in Central Africa. Wild grey parrots have been demonstrated to spend long periods of time exposed to bright sunshine rather than seeking shade (May D.I. 1996). This might be an attempt to increase either skin temperature or UVB received for improved vitamin D₃ metabolism.

The skin of mammals provides a rich source of endogenous vitamin D₃. The exposure of 1cm² of white human skin to direct sunlight for one hour has been shown to produce 10iu of cholecalciferol. On the basis of this exposure of the uncovered human face and hands to sunlight for 10 minutes per day is sufficient to provide adequate vitamin D₃. The maximum conversion of provitamin D₃ to previtamin D₃ occurs at the 297+/- 3nm wavelength (Holick M.F. & others 1982). Many factors alter cutaneous production of vitamin D₃ in mammals. The ability to utilise natural UVB radiation decreases with skin thickness. The increased melanin skin pigments in dark skinned people significantly increase their requirement for UVB radiation (Holick M.F. 1994). The ability to synthesise vitamin D₃ decreases dramatically with age: a person older than 70 years produces less than 30% of the quantity of vitamin D₃ as a young adult exposed to the same amount of sunlight (Holick M.F. & others 1989). The production of vitamin D₃ in the skin will depend on time of day, latitude and season (Holick M.F. 1994). Monochromatic light at 295nm has been shown to convert 7-dehydrocholesterol in the skin to provitamin D₃ with approximately 70% efficiency. This contrasts with exposure to full spectrum sunlight that has a conversion efficiency of only 20% (MacLaughlin J.A. & others 1982). Once sufficient previtamin D₃ has been formed additional solar radiation transforms the provitamin D₃ to biologically inactive compounds lumisterol and tachysterol (Holick M.F. 1994). This explains why hypervitaminosis D₃ has never been reported from excessive exposure to UVB light.

In poultry endogenous vitamin D₃ synthesis occurs on the featherless areas of the legs and face. Frequently the greatest impediment to vitamin D₃ synthesis in poultry is the

barrier to UVB provided by buildings. Even light transmitting materials such as glass do not transmit light in wavelengths below 334nm (Hess A. & others 1922). Chickens exposed to 30 minutes artificial UVB radiation whilst fed a vitamin D₃ deficient diet developed significantly less skeletal development problems than chickens denied supplementary UVB light (Edwards H.M. Jr, 2003, Mac-Auliffe T. & McGinnis J. 1976). The provision of ultraviolet fluorescent lighting has been demonstrated to reduce the incidence of tibial dyschondroplasia in broilers (Edwards H.M. Jr. & others 1992). Rachitic chicks significantly improve with exposure to UVB light (Mac-Auliffe T. & McGinnis J. 1976). Continuous ultraviolet irradiation on broiler chickens does not affect growth or food conversion efficiency in broilers but does lead to loss of corneal structure (Barnett K.C. & Laursen-Jones A.P. 1976). The measurement of 25 hydroxycholecalciferol has been shown to be a useful indicator of the UVB exposure of an individual (Horst R.L. & others 1981)). Poultry kept in the absence of ultraviolet light have been shown to require over 400IU/kg cholecalciferol content in their diet in order to grow normally (Edwards H.M. Jr. & others 1994). In mature laying pullets UVB supplementation has been shown to have no direct effect on the laying cycle though it does control behaviour in particular food intake (Lewis P.D. & others 2000).

The use of UVA (400-320nm) supplementation has been shown to significantly affect sexual behaviour in domestic broiler breeders increasing the number and quality of matings (Jones E.K. & others 2001). The colour vision of birds is based on absorption peaks in the green, blue red and ultraviolet regions of the spectrum. Recent studies in budgerigars have demonstrated that in the presence of ultraviolet light, vision may play an important role in mate and food selection in birds (Wilkie S.E. & others 1998). It has been shown that 72% of parrots have UV reflective plumage (Hausmann F. & others 2003, Pearn S.M. & others 2001).

Fluorescent tubes that provide some UVB radiation in addition to visible light are available commercially mainly designed for captive reptile exhibits (Logan T. 1969). The lights are lined with phosphorus and contain mercury. Once stimulated by electric discharge the mercury ionises inducing the phosphorus to emit UVB radiation. The success of these lamps to encourage vitamin D₃ metabolism depends on many factors. The glass used to

construct the tube, the type or amount of phosphorus used and the temperature of the light in use are important. In addition the phosphorus decays over a period of time so the lamps should be replaced regularly. The UVB radiation exposure of an individual animal will also depend on basking behaviour, distance from the light and the presence of UVB filters in the enclosure (Gehrmann W.H. 1996). As mentioned previously the success of UVB in stimulating vitamin D₃ synthesis will also depend on the temperature in the vivarium. Recently commercially available lamps have been marketed which produce both heat and UVB. These have been demonstrated to significantly increase the 25 hydroxycholecalciferol concentrations in Chuckwallas compared with lamps that do not generate heat (Aucone B.M. & others 2003). The UVB output of most lamps is described in terms of a percentage of UVB production rather than irradiance. In one study none of the commercial lamps produced significant amounts of UVB wavelength in the vitamin synthesis spectrum so care should be taken in lamp selection (Bernard J.B. 1995).

2.10 Disorders of calcium metabolism

2.10.1 Introduction

Disorders of calcium metabolism in healthy animals are prevented by the controlling influence of parathyroid hormone. The parathyroid glands are found at the thoracic inlet of the bird. They consist of loose cords of basophilic chief cells surrounded by connective tissue and sinusoids. The glands normally respond to hypocalcaemia by increasing their rate of secretion of parathyroid hormone from the chief cells. In severe cases of hypocalcaemia the glands enlarge due to rapid chief cell proliferation and the nucleus:cytoplasmic ratio of the cells decreases. Parathyroid gland disorders can be broadly grouped as hypoparathyroidism (where parathyroid hormone secretion is reduced) and hyperparathyroidism (where parathyroid hormone secretion is increased). Diseases of the parathyroid may be primary (where there is pathology present in the gland) or secondary (where a pathological condition away from the parathyroid gland affects mineral homeostasis).

2.10.2 Hyperparathyroidism

Hyperparathyroidism is a metabolic disorder expressed clinically by disturbances in mineral and skeletal homeostasis due to excessive parathyroid hormone secretion. Primary hyperparathyroidism is rare in domestic animals but has been reported in dogs and cats (Berger B. & Feldman E.C. 1987, Kallet A.J. & others 1991). It is usually associated with parathyroid neoplasia, in particular adenomas of the chief cells (Berger B. & Feldman E.C. 1987). There is an autonomous secretion of parathyroid hormone despite rising serum calcium concentrations. Affected animals present with anorexia, vomiting, constipation, depression and neuromuscular excitability. Clinical pathology demonstrates a hypercalcaemia, hypophosphataemia and increased serum parathyroid concentrations.

Secondary hyperparathyroidism is more common in domestic animals. In these cases the parathyroid gland reacts to a pathological disorder elsewhere in the body that has affected calcium homeostasis. The secretion of parathyroid hormone is excessive in response to falling serum ionised calcium concentrations but not autonomous as in cases of primary hyperparathyroidism. The 2 main forms of secondary hyperparathyroidism are renal secondary hyperparathyroidism and nutritional secondary hyperparathyroidism.

Renal secondary hyperparathyroidism is a sequel to chronic renal failure. It is common in dogs with chronic renal insufficiency. The failure of the diseased kidney to metabolise vitamin D₃ contributes to increased parathyroid hormone secretion. The kidneys fail to excrete phosphate leading to a rise in serum phosphate concentrations and a concurrent fall in ionised calcium concentrations. The parathyroid gland becomes hyperplastic and increases parathyroid hormone secretion to maintain normocalcaemia by increasing bone resorption. In poultry it has been demonstrated that the kidney becomes refractory to the increased circulating PTH due to loss of PTH receptors in the renal plasma membranes (Forte L.R. & others 1982). The cancellous bones of the maxilla and mandible are sites of predilection for bone resorption in renal secondary hyperparathyroidism leading to softened jaws ("rubber-jaw disease"). The long bones of the abaxial skeleton are less frequently affected.

Nutritional secondary hyperparathyroidism is a sequel to a nutritional imbalance characterised by an increase in parathyroid hormone secretion in response to a

disturbance in mineral homeostasis. Nutritional hyperparathyroidism is typically seen in animals fed a diet with low calcium but high phosphate levels or diets with inadequate vitamin D₃. All these dietary imbalances lead to hypocalcaemia and stimulation of the parathyroid glands. As renal function is normal the increased parathyroid hormone secretion leads to increased renal phosphate excretion and calcium absorption. If the imbalanced diet continues to be supplied the continued state of compensatory hyperparathyroidism leads to metabolic bone disease. There is a gradual loss of skeletal density and eventually pathological fractures develop. It has been reported in cats and dogs fed a non-supplemented meat diet and in horses fed a high grain-low roughage diet characteristically containing excessive amounts of phosphorus. High dietary phosphorus has direct effects on parathyroid hormone synthesis and secretion. It also has an indirect action by its ability to reduce blood calcium when serum becomes saturated with both ions. In New World monkeys failure to provide adequate dietary vitamin D₃ has been associated with nutritional secondary hyperparathyroidism. It has also been reported in captive birds, lions, tigers, iguanas and crocodiles. Under chronic hypocalcaemic conditions, parathyroid hormone fulfils its chemical role in calcium homeostasis at the expense of skeletal integrity. Uncorrected hypocalcaemia results in fibrous osteodystrophy of the skeleton. Chronic over stimulation of bone by parathyroid hormone is almost exclusively responsible for the development of fibrous osteodystrophy (Woodard J. 1996) in which disproportionate osteoclasts precedes fibrous tissue proliferation in an attempt to counter the loss of mechanical strength (Taylor T.G. & Dacke C.G. 1984). Fibrous tissue and reactive woven bone have less structural integrity, predisposing to deformation and pathologic fracture (Taylor T.G. & Dacke C.G. 1984). The lesions seen in osteodystrophy occur as a result of excess PTH, not as a direct result of electrolyte imbalances (Woodward J. 1996). It has been demonstrated that high circulating concentrations of PTH reduce the expression of the PTH/PTHrP receptor gene in avian epiphyseal growth plates (Pines M. & others 1999).

2.10.3 Histological appearance of the parathyroid gland in nutritional secondary hyperparathyroidism (figure 6)

Histological changes in the appearance of the parathyroid gland can be used to predict the nature of disorders of calcium metabolism. The ultrastructure of the parathyroid glands of growing chickens with rickets has been described (Okada K. & others 1983). Four cells were identified in both abnormal and normal control birds: type 1 cell (small cell in resting phase): type 2 cell (medium sized cell with well developed rough endoplasmic reticulum in synthesising phase): type 3 cell (large cell with well developed golgi apparatus and many cytoplasmic organelles in secretory and packaging phases): type 4 cell (medium sized cell with few cytoplasmic organelles in involution phase). In normal young chickens the majority of parathyroid gland cells are type 1 cells in the resting stage. With age more type 3 cells would develop in the synthesising stage in normal birds. The principal cells in young birds with rickets are mainly type 3 secretory cells with a few involuting type 4 cells. Other studies have determined the pathology of vitamin D₃ deficiency through both bone and parathyroid gland structure (Cheville N.F. & Horst R.L. 1981). Essentially the parathyroid glands were enlarged, irregular and vacuolated containing few secretory granules. The metaphyses were also 5 times longer in vitamin D₃ deficient chicks with numerous osteoclasts and osteoblasts.

The histological effect of nutritional secondary hyperparathyroidism has been studied in parakeets (Arnold S.A. & others 1973). The birds were fed a cereal-based diet with calcium to phosphorus ratio of 1 to 37. At necropsy the parathyroid glands were grossly enlarged compared with birds fed a supplemented diet. Histological examination of the parathyroid gland of non-supplemented birds showed hypertrophic chief cells and considerable vacuolation. Supplemented birds had smaller chief cells. The femurs of unsupplemented birds showed significant osteolysis compared with supplemented birds. Parathyroid gland hyperplasia has been demonstrated in a macaw kept on a diet with a low calcium and vitamin D content (Roskopf W.J. & others 1981). Feeding a mature female bird a diet deficient in vitamin D, calcium or phosphorus will lead to decreased medullary bone volume. After longer periods all the medullary bone would be resorbed (Wilson S & Duff S.R. 1991).

2.10.4 Hypoparathyroidism

Hypoparathyroidism results from either an inability of the parathyroid gland to secrete adequate parathyroid hormone or a failure of the hormone to interact with target cells. The disease is rare in domestic animals although it has been reported in dogs and cats. It is usually associated with iatrogenic removal of the parathyroid glands during thyroidectomy in cats. Idiopathic hypoparathyroidism has been associated with atrophy of the parathyroid glands possibly with an immune mediated aetiology (Bruyette D.S. & Feldman E.C. 1988, Peterson M.E. & others 1991). The disease is characterised by increased neuromuscular excitability and tetany associated with low serum ionised calcium, normal or elevated phosphate and low PTH concentrations.

2.10.5 Hypocalcaemia in grey parrots

The concentration of calcium in the extracellular fluid is critical for many physiological purposes. In the normal bird serum ionised calcium concentration is kept within a tight range as in mammals. Signs typical of hypocalcaemia occur when there is a failure of the parathyroid controlled homeostatic mechanisms that normally protect against falling blood calcium concentrations. The most common causes for hypocalcaemia in mammals are hypoparathyroidism, vitamin D₃ deficiency and abnormal vitamin D₃ metabolism.

Hypocalcaemia is a commonly recognised syndrome in captive grey parrots although the aetiology is still unconfirmed and it is rarely reported in other psittacine species (Randell M.G, 1981, Roskopf W.J. & others 1981, Roskopf W.J. & others 1985, Arnold S.A. & others 1973). The condition has traditionally been attributed to feeding diets with a low vitamin D₃ and calcium content leading to nutritional secondary hyperparathyroidism (Fowler M.E. 1978, Roskopf W.J. & others 1985). These diets are also typically high in phosphate, which forms phylate complexes with the calcium reducing bioavailability of the mineral. This does not explain why grey parrots are so well represented with the syndrome compared with other psittacine birds fed similar diets. Alternative explanations would be a

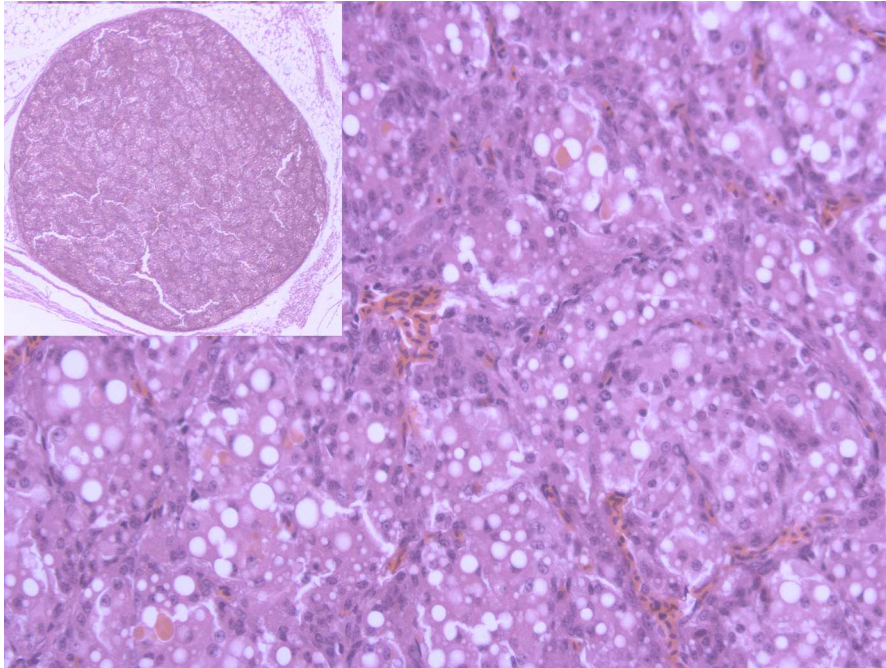


Figure 6. Parathyroid gland from a juvenile peregrine falcon (*Falco peregrinus*) with nutritional secondary hyperparathyroidism. The bird presented with bilateral pathological fractures of the tibiotarsi. The gland demonstrates hypertrophy of the chief cell with evidence of vacuolation throughout the gland. (Haematoxylin and eosin, 20X magnification main image, insert 2X magnification).

genetic predisposition to primary hypoparathyroidism or a failure of adequate vitamin D₃ metabolism (including genetic defects in the vitamin D receptors) . The signs in adult birds are similar to those for acute hypocalcaemia in man resulting from enhanced neuromuscular irritability (Shane E. 1999). These range from slight ataxia and head twitching to full seizures. The wings are usually extended with severe loss of coordination and the birds may exhibit nystagmus with pronounced facial twitching. The birds show irritable and abnormal behaviour. The seizures rapidly respond to treatment with vitamin D₃ or calcium. It has been shown that grey parrots respond more quickly to treatment for hypocalcaemia using vitamin D₃ medication than calcium supplementation (Hochleither M. & others 1997).

The captive breeding of psittacine birds has increased dramatically in the last decade. Hypocalcaemia in captive bred grey parrot chicks presents as juvenile osteodystrophy with deformity of the long bones and pathological fractures identified radiographically (Harcourt-Brown N.H. 2003). Sexually mature female grey parrots can present with egg binding or osteoporosis (Macwhirter P. 1994). Egg binding is normally due to oversized, over produced or malpositioned eggs rather than an absolute calcium deficiency although treatment is frequently successful with calcium supplementation (Roskopf W.J. & Worpel R.W. 1984). Birds can produce poor quality egg shells or deformed eggs in a similar manner to domestic poultry fed a diet containing low calcium or vitamin D₃ (Hurwitz S. 1989). As laying hens age they lose the ability to adapt to changes in calcium intake increasing the probability of thin shelled eggs (Bar A. & Hurwitz S. 1987, Bar A. & others 1999)

Hypercalcaemia is rarely reported in birds. It has been found as a paraneoplastic effect of malignant lymphoma in two Amazon parrots (de Wit M. & others 2003). The response of the parathyroid gland and ultimobranchial body to experimental hypercalcaemia has been studied in the Indian ring neck parakeet (*psittacula psittacula*) (Swarup K. & others 1986). The ultimobranchial cells show progressive hypertrophy. The parathyroid gland cells demonstrated hypotrophy under the influence of chronic hypercalcaemia.

2.11 Skeletal development in birds

2.11.1 Normal skeletal development in birds

The normal growth and development of the avian skeleton is reviewed in Stark and Ricklefs (1998). The requirement for flight in most birds dictates distinct skeletal differences from mammals. The avian skeleton is kept light by the pneumatisation of some bones and the fusion of others such as the synsacrum. In individual bones where strength is required there is an increased bone density compared with the mammalian equivalent (Howlett C.R. 1978). Birds are classified into two groups: altricial birds and precocial birds. The basic distinction between the two groups was first made by Oken (1837). Altricial nestlings hatch featherless and with their eyes closed. They remain in the nest for the majority of their development (nidicolous) during which time they are totally dependent on their parents for food and protection exhibiting little motor activity other than begging. Altricial nestlings grow rapidly on average three to four times more quickly than precocial birds (Ricklefs R.E. & others 1998). Precocial birds such as quail hatch feathered, with eyes open and able to fend for themselves away from the nest from an early age. The basic distinction between altricial and precocial birds has not been altered to the present time although the 2 groups have been further subdivided. Parrots are altricial birds and although they grow quickly compared with precocial birds, they are considered one of the slowest growing altricial birds.

It has been established that the eggshell is the major source of calcium for skeletal development in the avian embryo (Tuan R.S. & others 1991). Domestic fowl embryos mobilise calcium between days 7 and 8 of incubation corresponding to the onset of skeletal mineralisation. Initially the egg yolk provides calcium for skeletal mineralisation but by day 10 of incubation calcium is mobilised from the eggshell. At the end of incubation 80% of the calcium found in the embryo has been provided from the eggshell (Simkiss R. 1975). Hamburger and Hamilton (1951) published a classification of the normal stages of development for domestic fowl. The 42 stages of normal embryonic development described can be applied equally well to precocial and altricial birds for all the species researched at the present time including the budgerigar (*Melopsittacus undulatus*) although the larger

parrots have not been studied (Stark J.M. 1989). The early embryonic stages are approximately the same in length in all species but the later stages deviate between altricial and precocial birds. This has been shown to account for the variation in egg incubation time between the two groups (Stark J.M. 1989). The development of the embryonic skeleton in precocial and altricial birds has been studied by Stark (1996). In all the species researched to the present time the skeletal elements ossify in identical sequence with little variation in the number of ossifications present at hatching. There is considerable variation, however, between species in the degree of ossification at hatching. It is suggested that there is a relationship between postnatal growth rate and degree of ossification at hatching (Stark J.M. 1994). The skeleton has three main functions in young birds, to provide support for the musculature, and to resist the mechanical forces from both growth and locomotion. Although the skeleton of precocial hatchlings would be expected to provide all three functions in altricial hatchlings the skeleton's primary function would be support with limited locomotive forces

Avian growth plates differ from mammalian, consisting of 5 cartilaginous zones (figure 7): germinal, proliferative, prehypertrophic, hypertrophic and calcifying zones (Howlett C.R. 1978). The chondrocyte arrangement varies from columnar to pleomorphic through these zones. Long bones lengthen by growing from a zone of proliferation equivalent to a growth plate in mammals. The epiphyseal portion of the bone is unossified cartilage and the end of the bone is not evident radiographically in birds (figure 8, Fowler M.E. 1981). It has been demonstrated that the difference in rate of elongation of the tarsometatarsus is proportional to the height and width of the zone of proliferation (Kirkwood J.E. & others 1989, Kember N.F. & others 1990). It has been suggested that the growth rate of the tarsometatarsus could be the same as the rest of the skeleton. Altricial birds have larger cartilaginous zones than precocial birds, which explains the faster growth rate of altricial birds compared with precocial species (Stark J.M. 1996). The cartilage volume of neonatal birds has been shown to vary from 50% in precocial birds to 90% in altricial species. The mechanical strength of the bones would be expected to be inversely proportional to the cartilage cell volume. The high mechanical strength required by precocial birds for motor activity due to

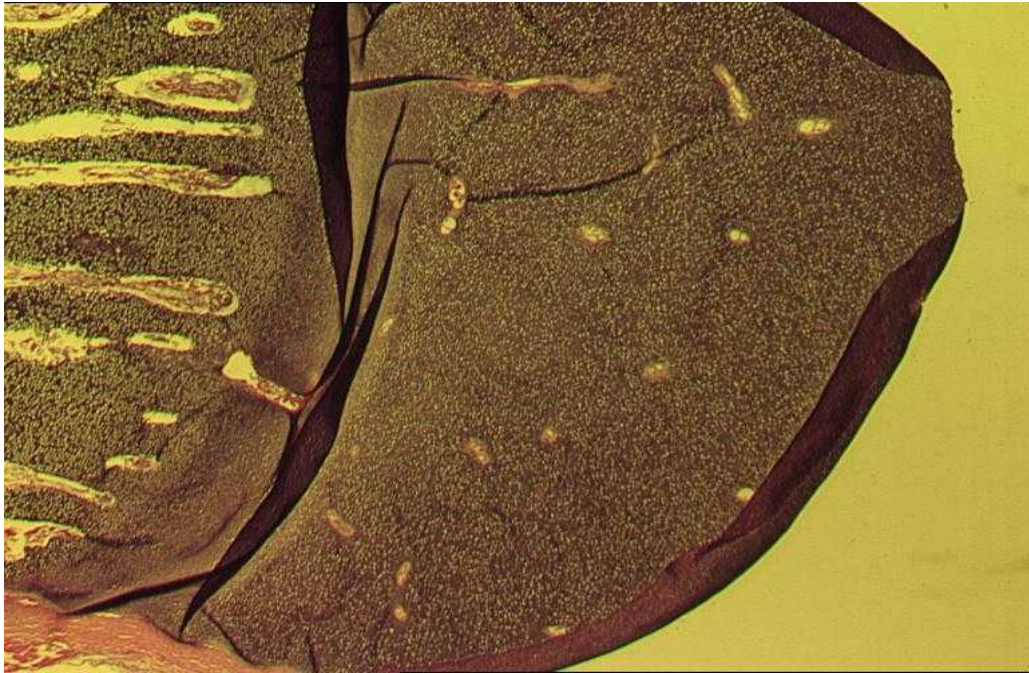


Figure 7. Normal histological appearance of the avian growth plate. The growth plate consists of 5 distinct layers.

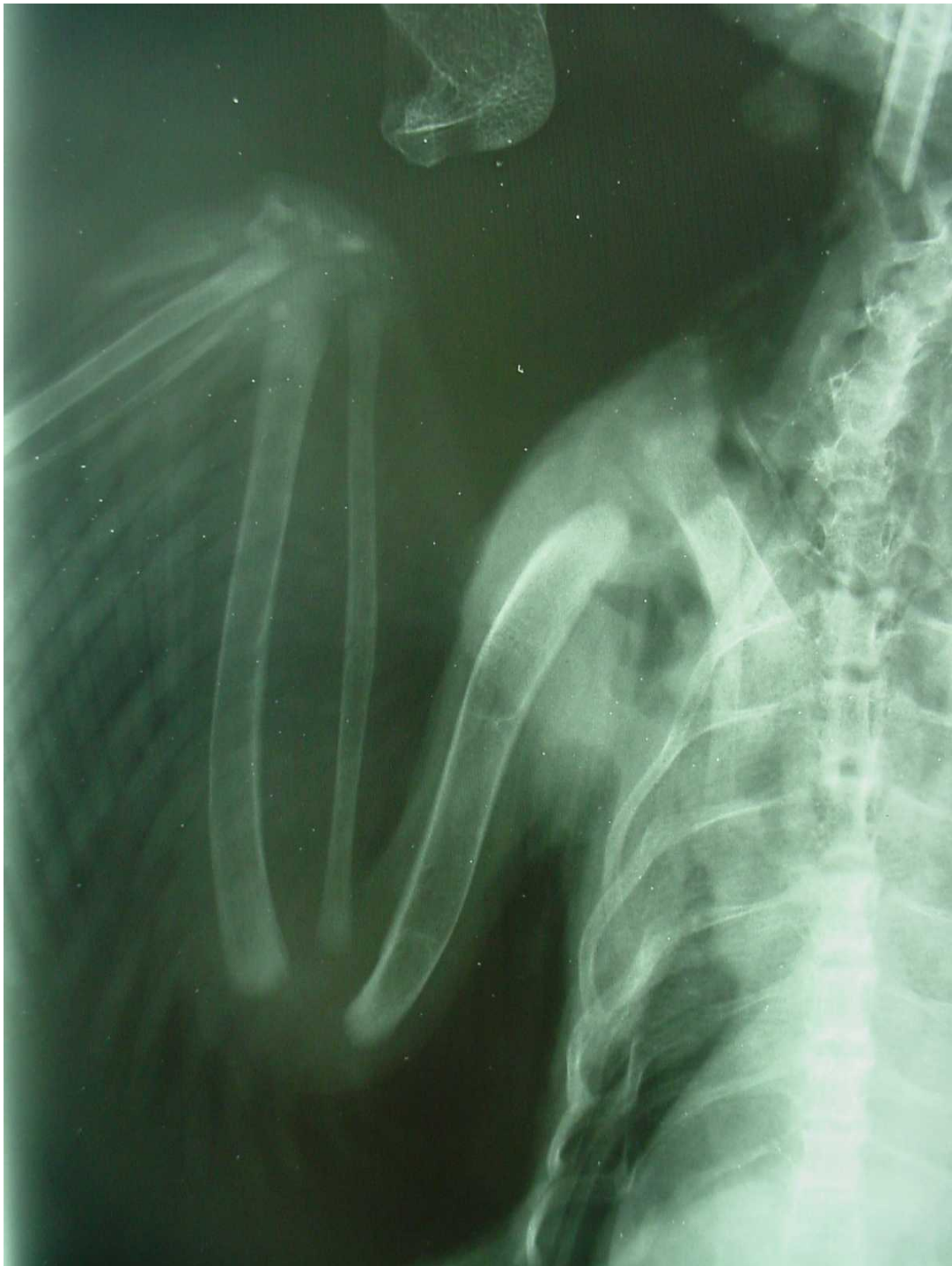

Figure 8. Normal radiographic appearance of the avian growth plate. This demonstrates that the avian growth plate consists of unossified cartilage not visualised on radiographs.

their independence from birth would be expected to reduce their growth rate. This relationship between skeletal growth and function has been demonstrated in the Californian gull (*Larus californicus*) by Carrier & Leon (1990). The Californian gull is a semi-precocial bird (able to walk from an early age but fed by their parents). They have thick pelvic limb bones allowing them to be mobile from an early age without the growing pelvic limb bones becoming deformed. The birds do not fly until they are fully developed so the wing bones remain weak and undeveloped until a few days before fledging. There is a period of rapid wing growth prior to the start of wing activity. The bone in the wing is reorganised histologically and attains high mechanical strength. It has been demonstrated in the Californian gull that the rate of long bone elongation in the wing may act as a limiting factor for fledging time (Carrier D. & Auriemma J. 1992). The relationship between skeletal development and function has also been studied in the parrot (Harcourt-Brown N.H. 2004). The study examined the rate and cessation of growth of each long bone by radiography in naturally reared dusky parrots (*Pionus fuscus*). The pelvic limb bones had finished growing by 39 days, the wing bones by 47 days. Observation of the behaviour of the birds revealed no vigorous activity such as climbing or flapping until bone growth was complete. It was noted that an isolated bird would stand and walk around if given the opportunity. If the same bird was placed in contact with siblings it would huddle into them. This huddling behaviour would help conserve body heat but it could also provide natural support to the growing bird. Any factor that might increase the locomotor activity of altricial birds could jeopardise normal bone development. Parrots bred in captivity are frequently artificially reared by syringe or spoon-feeding. They are removed from the parents after hatching and kept individually in small plastic boxes without the support of their siblings (figures 9 & 10). The birds are usually very mobile in these boxes, especially at feeding time. It has therefore been suggested that hand rearing altricial parrots might be a factor in the development of osteodystrophy by removing the support of siblings combined with increased motor activity (Harcourt-Brown N.H. 2003, Harcourt –Brown N.H. 2004)



Figure 9. Traditional method of hand rearing parrots. The birds are kept individually in small plastic containers. The birds would not be expected to receive the support from their siblings that might occur in a normal nest.

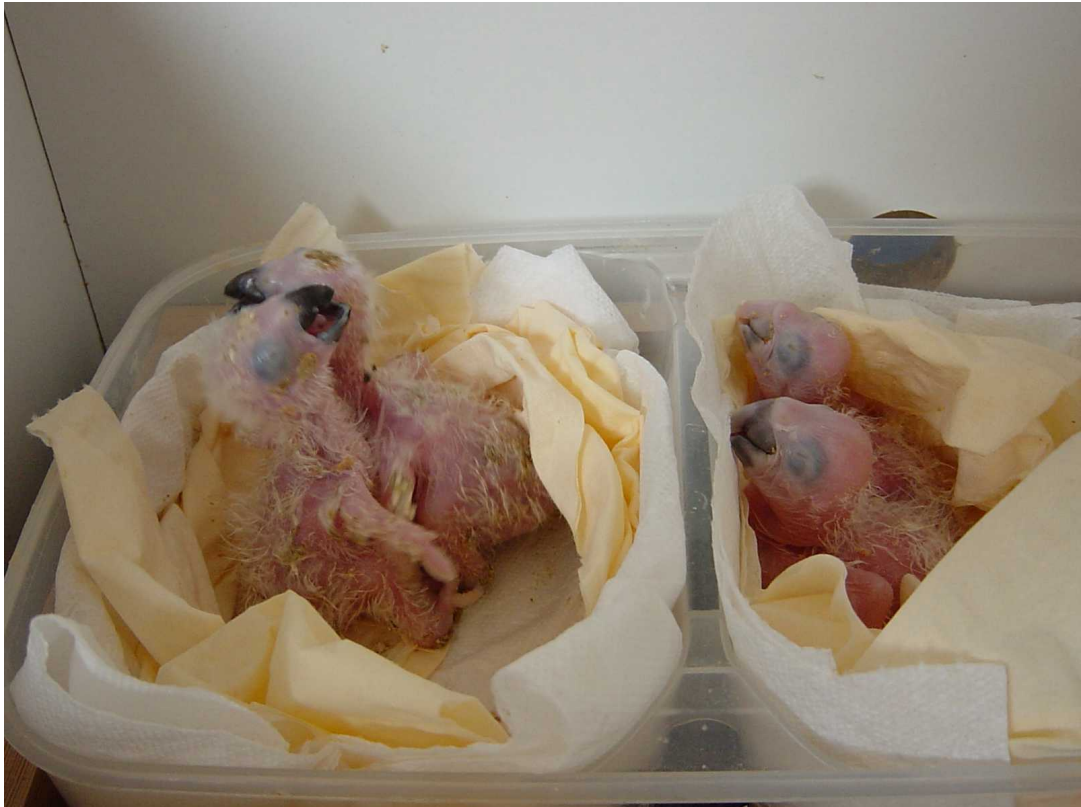

Figure 10. Grey parrots hand reared in small groups in artificial nests. This might be expected to provide more support to the rapidly growing bones than rearing the birds individually.

2.11.2 Abnormal skeletal development in birds

Metabolic bone disease is a non-specific term used to describe morphological defects that can occur during bone growth or remodelling of the adult skeleton. Metabolic bone disease occurs when there is a failure of cartilage or bone matrix production, or in their maintenance or mineralisation. Although metabolic bone disease is usually due to primary nutritional deficiencies it can also be associated with hormonal effects, physical factors, toxins and poor utilisation of nutrients (Edwards H.M. Jr. 1992). The term encompasses osteoporosis, osteosclerosis, fibrous osteodystrophy, rickets (osteodystrophy) and osteomalacia (the equivalent of rickets in the skeletally mature animal).

Osteodystrophy is defined as the failure of normal bone development. Clinically, osteodystrophy presents as distortion of bone, with associated increased susceptibility to pathological fractures and abnormalities of both gait and posture (Blood D.C. & Studdert V.P. 1988). A similar disorder in children would be rickets described as a disorder of bone mineralisation in growing bone. Osteodystrophy involves both the growth plate (epiphysis) and newly formed trabecular and cortical bone. Osteomalacia is also defined a disorder of bone mineralisation but only occurs after cessation of growth. Rickets can be caused by a vitamin D₃ or calcium deficiency in children (Klein G.L. & Simmons D.J. 1993). Historically rickets was found in children fed poor diets deficient in vitamin D₃ with limited exposure to natural light. Exposure to ultraviolet light or supplying vitamin D₃ in the diet prevents the clinical signs of rickets (O'Riordan J.L.H. 1997). In the western world rickets is now rare due to the fortification of dietary staples such as milk and bread with vitamin D₃ (Stamp T.C.B. 1975). Rickets is usually only seen in children relying on total parenteral nutrition with inadequate calcium and vitamin D₃ levels (Klein G.L. & Chesney R.W. 1986). It is also common in Asian women who traditionally wear veils, which reduce their exposure to sunlight. Rickets has been reported in many different animal species kept in captivity (Fowler M.E. 1986, Boyer T.H.1986). Rickets is commonly described in New World monkeys in captivity where the adequate provision of ultraviolet light is an important part of their husbandry (Fiennes R.N. 1974, Miller R.M. 1971). Metabolic bone disease is common in carnivores fed an all meat diet with high phosphorus to calcium ratio (Freedman M.T. & others 1976). Metabolic bone disease is one of the most common disorders seen in

captive reptiles, deprived of adequate ultraviolet light creating a vitamin D₃ deficiency (Fowler M.E. 1986).

Osteodystrophy has been demonstrated in many species of birds radiographically (Kostka V. & others 1988). It has been postulated that feeding a diet with inadequate calcium and vitamin D₃ is responsible for the development of osteodystrophy in young poultry (Fowler M.E. 1978). The disease does, however, appear to be multifactorial and factors including genetics (Kestin S.C. & others 1999), growth rate (Classen H.L. 1992) and exercise (Classen H.L. & Riddell C. 1989) have all been implicated in addition to diet. Although there are similarities between the clinical presentation and aetiology of rickets in mammals and juvenile osteodystrophy in birds the normal bone development of birds is quite different. Bone development in birds has been extensively researched in the pelvic limb of both poultry and turkeys although little work has been carried out in parrots. The main difference between mammal and birds is that the epiphysis does not calcify until the end of their growth period in birds. Radiographically the proximal and distal ends of the femur and the proximal end of the tibiotarsus are absent until the growth period has finished. The growth of cortical bone in female broilers has been demonstrated to differ from male individuals with mineralisation proceeding at a greater rate (Rose N. & others 1996). This might explain why deformations of the intertarsal joint are less common in female broiler chickens.

There have been several excellent reviews of nutritional and skeletal problems in poultry (Edwards H.M. Jr. 1992, Edwards H.M. Jr. 2000). Skeletal disorders in commercial poultry are commonly and responsible for considerable economic loss in the industry. In broiler flocks the incidence of skeletal abnormalities was found to be 1.72% (Riddel C. & Springer R. 1985). Classification of skeletal disorders is difficult but they can be classified according to the pathogenesis of the condition i.e. developmental, degenerative or metabolic (Riddell C. 1991). In this review only metabolic skeletal conditions in poultry with a nutritional basis will be considered in detail.

Rickets is a disease of young growing poultry, which develop poorly mineralised bones, combined with thickened, irregular growth plates. The disease is rarely seen in egg laying birds. The clinical signs develop due to inadequate mineralisation of both bone and

cartilage in response to a dietary lack of vitamin D₃, calcium or phosphorus (Riddell C. 1981). An imbalance between dietary calcium and phosphorus can also lead to rickets (Riddell C. & Pass D.A. 1987). In addition, poor food mixing has also been associated with rickets in poultry. Other dietary components may interfere with the utilisation of vitamin D₃ by poultry including diets containing high levels of vitamin A, which competitively binds to the same receptors as vitamin D₃ (Stevens V.I. & others 1983). Although nutritional aetiologies are responsible for the development of rickets in poultry selected strains are found to be more susceptible (Austic R. & others 1977).

The clinical signs of rickets have been described (Groth W. 1962, Groth W. & Frey H. 1966, Long P.H. & others 1984). Necropsy of affected birds reveals bones that are soft and bend easily with thickened growth plates. Histologically there is a failure of endochondral ossification and lack of mineral deposition (Takechi M. & Itakura C. 1995). There is distinctive metaphyseal flaring, enlargement of the growth plate with pathological fractures common. If rickets has a nutritional aetiology (nutritional secondary hyperparathyroidism) osteoclasts of calcified bone is seen which is not a common finding in uncomplicated rickets (Woodward J. 1996). The hypertrophic cartilaginous zone of the growth plate enlarges as a result of insufficient vitamin D₃ metabolites or lack of calcification (figures 11-15). The process of chondroclastic resorption and subsequent calcification are defective. There is an excess of osteoid due to osteoclasts failing to adhere to its surface. Fibrous tissue is a common finding replacing mature bone. Lack of mineralisation in growing bone leads to valgus of the long bones. It is possible to deduce the nutritional deficiency in chickens by analysis of the growth plate pathology (Wise D. 1975). Clinical signs of rickets are significantly reduced in poultry fed a vitamin D₃ deficient diet if they are exposed to 30 minutes of ultraviolet radiation daily from day 1 (Edwards H.M. Jr. 2003). This correlates well with immature parrots traditionally reared indoors on diets containing inadequate levels of vitamin D₃ and calcium with limited exposure to ultraviolet light.

Tibial dyschondroplasia is a common cause of lameness in rapidly growing poultry with an incidence of 1-40% (Friedmann J. 1977, Prasad S. & others 1972). It is characterised by a mass of unmineralised cartilage extending distally from the tibiotarsal growth plate leading




Figure 11. Growth plate of a 6 week old grey parrot with juvenile osteodystrophy. There is an increase in the length of the hypertrophic zone of the growth plate.

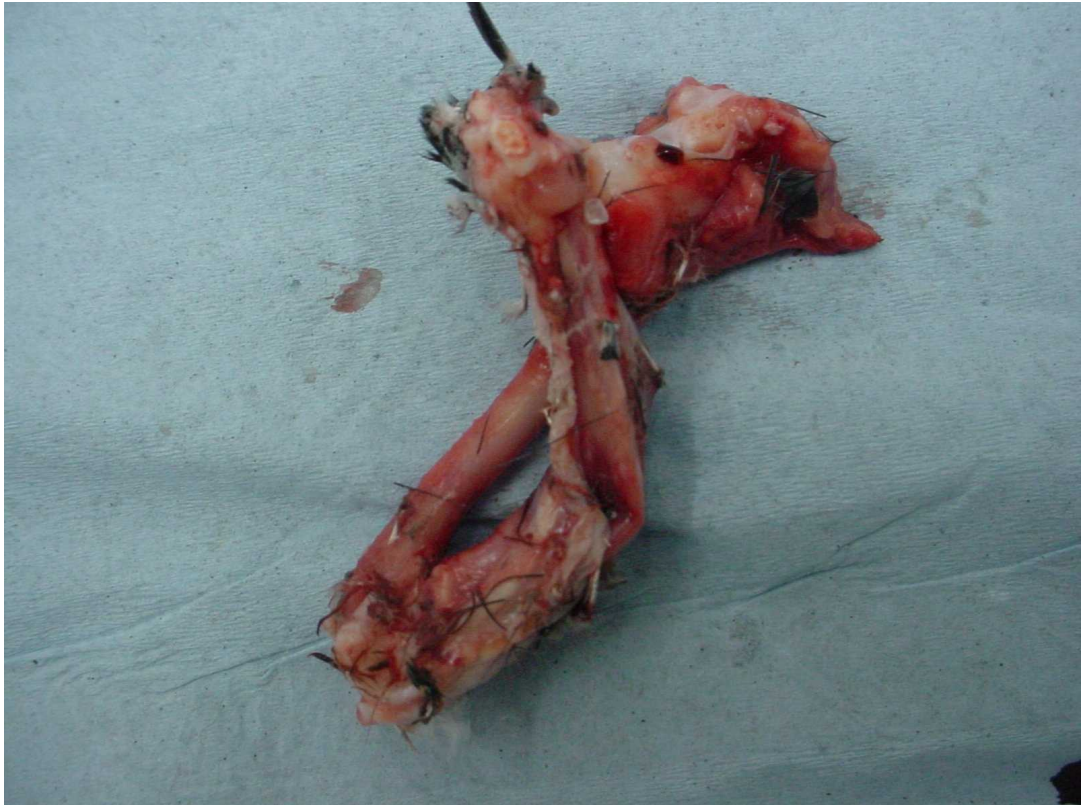


Figure 12. Humerus, radius and ulna from a grey parrot euthanased due to severe juvenile osteodystrophy. The bones are very flexible with replacement of normal bone by fibrous tissue.

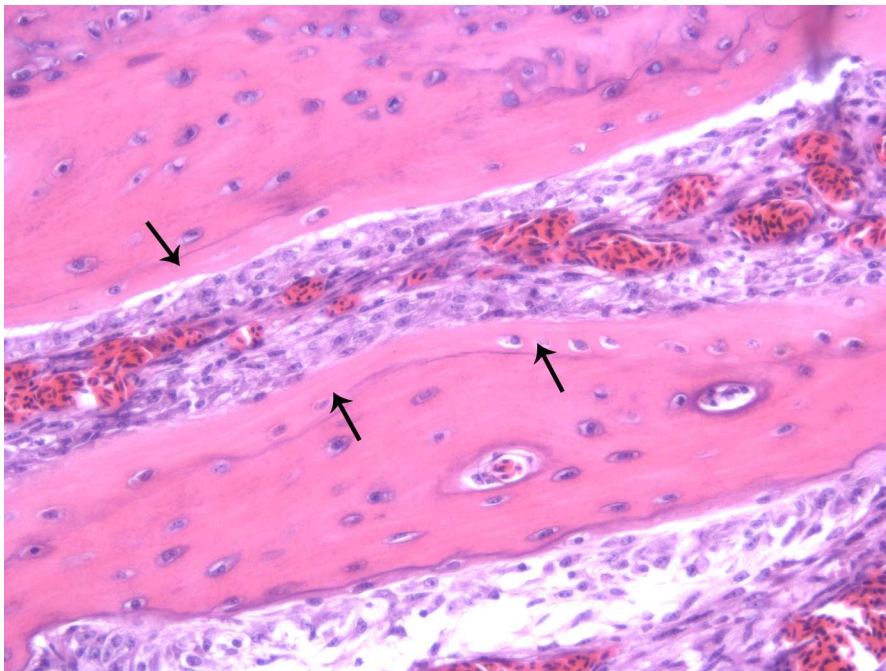


Figure 13. Cortical bone of the humerus from a grey parrot with juvenile osteodystrophy. The arrows indicate peripheral unmineralised osteoid seams, consistent with osteodystrophy. Fibroblasts fill the space between the two areas of bone, consistent with fibrous osteodystrophy. (Haematoxylin and eosin, 200X).

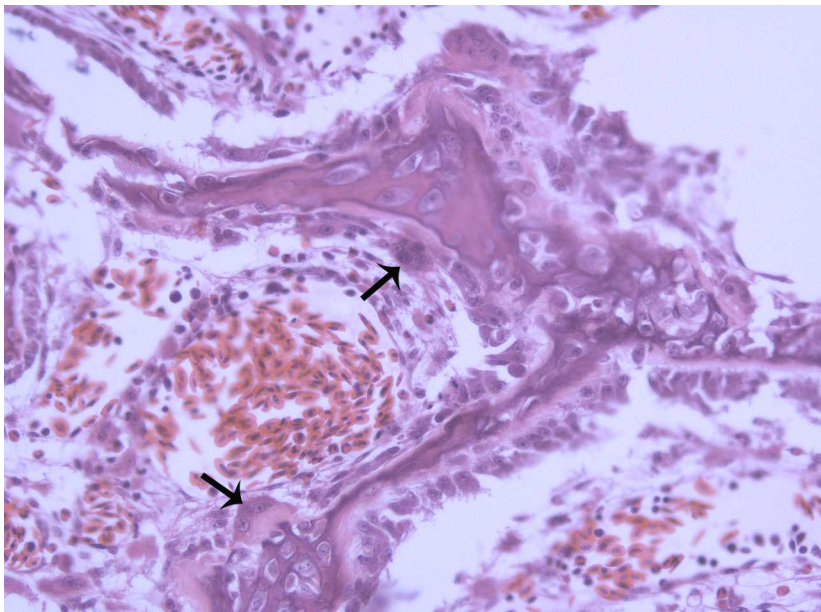


Figure 14. Subchondral medullary bone from the humerus of a grey parrot with juvenile osteodystrophy. Significant numbers of fibroblastic spindle-shaped cells separate trabeculae, which are lined by numerous osteoclasts (arrows). These lesions are consistent with secondary hyperparathyroidism. (Haematoxylin and eosin 200X).

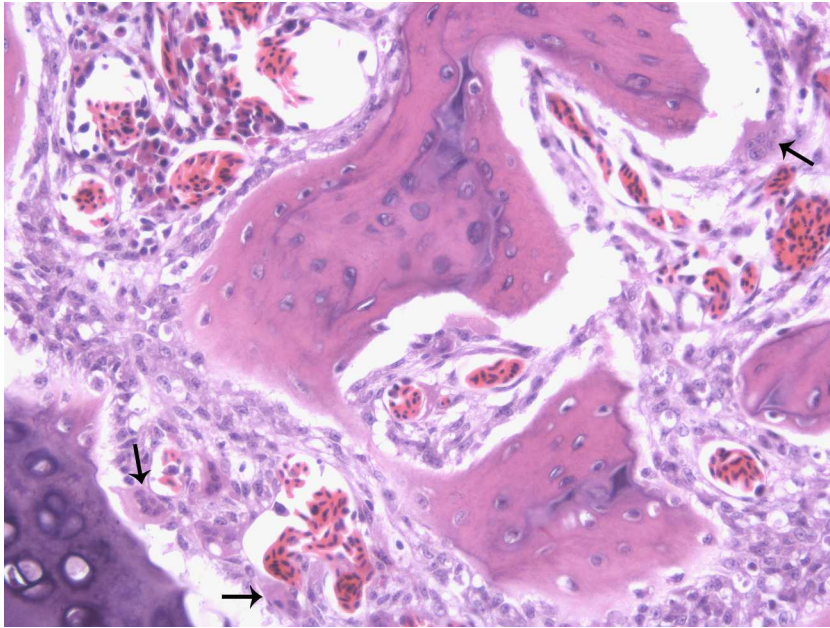


Figure 15. Medullary bone from the tibiotarsus of a grey parrot with juvenile osteodystrophy. The medullary bone in the tibiotarsus is lined by plump (active) osteoblasts. Centrally the trabeculae are mineralised but they have pale-staining eosinophilic peripheral seams of unmineralised osteoid. The numbers of osteoclasts (arrows) are increased on mineralised and unmineralised surfaces.

to both deformity and lameness (Berry J.L. & others 1996). Although the aetiology is unknown it is closely related to the growth rate of the chick (Kiiskinen T. & Anderson P. 1982). It is only partially responsive to dietary supplementation (Elliot M.A. & others 1995, Mitchell R.D. & others 1997a, Rennie J.S. & others 1995, Rennie J.S. & others 1997). Ultraviolet lighting has been demonstrated to be more effective than dietary cholecalciferol supplementation in preventing the development of tibial dyschondroplasia (Elliot M.A. & Edwards H.M. Jr. 1997, Edwards H.M. Jr. 2003). Specific genetic broiler lines are susceptible to tibial dyschondroplasia (Farquharson C. & Jefferies D. 2000, Mitchell R.D. & others 1997b).

Cage layer osteoporosis is the most significant skeletal metabolic bone disease in adult commercial poultry used for egg production (Riddell C. 1992). It is characterised by fragile bones and pathological fractures (Riddell C. 1981). The birds become paralysed in their cages and some cases die suddenly. It has been postulated that these sudden deaths may be attributed to low blood ionised calcium concentrations. Necropsy changes are consistent with both osteomalacia (decreased bone density) of medullary bone and osteoporosis (decrease in bone volume without loss in density) of cortical bone. Cage layer osteoporosis is considered a nutritional disease caused by a vitamin D₃, calcium or phosphorus deficiency (Antillon A. & others 1977). It has also been suggested that lack of activity predisposes to osteoporosis as birds kept in cages have weaker bones than free range birds (Knowles T.G. & Broom D.M. 1990). The susceptibility of productive chickens to osteoporosis is related to the high demand for calcium for eggshell formation as during peak production females obtain calcium from medullary bone forming at the expense of cortical bone, rather than from the diet (Etches R.J. 1987). If the diet contains inadequate calcium, phosphorus or vitamin D₃ osteoporosis develops (Wilson S. & Duff S.R. 1991). Osteoporosis is not reported in adult psittacine birds. This might reflect the limited egg production expected from an individual parrot compared with production poultry.

Angular and torsional deformities are common in poultry (Duff S.R.I. & Thorp B.H. 1985, Randall C.J. & Mills C.P.J. 1981) and presents as "twisted leg" syndrome. Prevalence varies from 0.5% to 25% in growing fowl (Julian R. 1984). Although it is mainly described in the tibiotarsus and tarsometatarsus limb deformity can also occur in the other long bones

(Duff S.R.I. & Thorp B.H. 1985). In poultry normal patterns have been described for long bone torsion in the femur, tibiotarsus and tarsometarsus under different husbandry conditions (Duff S.R.I. & Thorp B.H. 1985). It is known that mechanical factors are a predisposing factor for torsional or skeletal disorders in poultry (Reiland S. & others 1978). Lack of exercise in cages for example is considered a common cause of twisted legs (Haye U. & Simons P.C.M.1978).

Rapid growth, altered load bearing or different functional activity may lead to abnormal torsional activity in poultry (Duff S.R.I. & Thorp B.H. 1985). It has been postulated that the hand rearing of young psittacine birds may predispose to osteodystrophy due to increased activity and lack of sibling support (Harcourt- Brown N.H. 2004). Osteodystrophy is common in juvenile grey parrots. In one study of 34 feather picking juvenile grey parrots 15 birds (44%) had radiographic evidence of osteodystrophy (Harcourt-Brown N.H. 2003). Juvenile grey parrots are frequently presented with pathological fractures of the tibiotarsus (figures 16,17 & 18). These birds have normally been fed a cereal-based diet with inadequate calcium and vitamin D₃ content. This is a well recognised as a cause of osteodystrophy in poultry (Edwards H.M. Jr. 1992).

2.11.3 Relationship between nutrition and leg disorders in poultry

Leg abnormalities in poultry are multifactorial involving environmental, genetic and nutritional factors. The important role of nutrition in the aetiology of leg disorders of poultry has been well known since 1923 (Mitchell H.H. & others 1923). There are several reviews relating to nutritional and leg disorders (Pierson F.W. & Hester P.Y. 1982, Sauveur B. 1984, Sauveur B. 1986, Leeson S. & Summers J.D. 1988, Whitehead C.C. 1989, De Groote G. 1989, Edwards H.M. Jr. 1992)

Cod liver oil was first used to prevent rickets in poultry in 1922 (Hart E.B. & others 1922). By the 1930s the impurity in the cod liver oil that was responsible for the antirachitic properties was found to be 7-dehydrocholesterol (provitamin D₃). It was demonstrated that

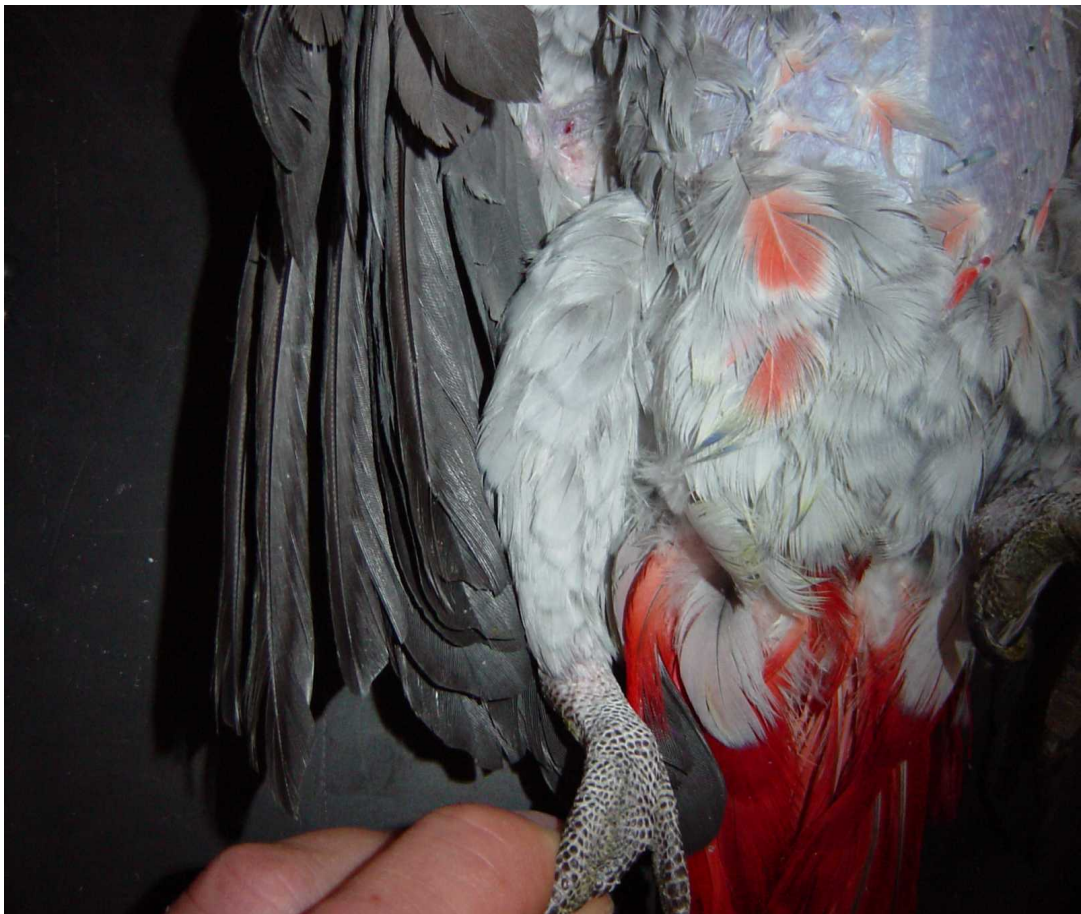


Figure 16. Juvenile osteodystrophy in a 12 week old hand reared grey parrot. There is severe bowing of the tibiotarsus.

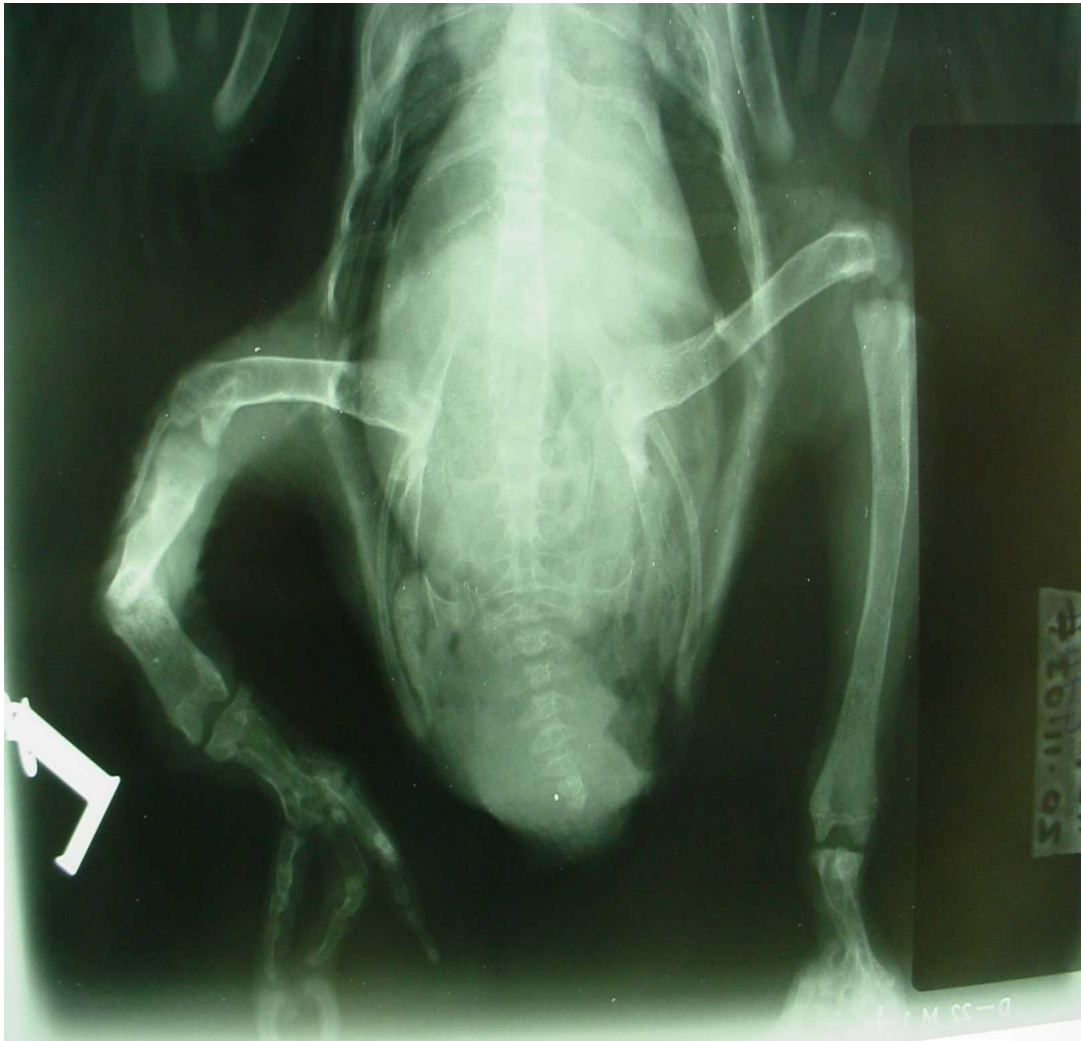

Figure 17. Radiograph of the grey parrot in figure 16. There is a pathological fracture of the tibiotarsus. The bird was euthanased due to the severity of the condition.

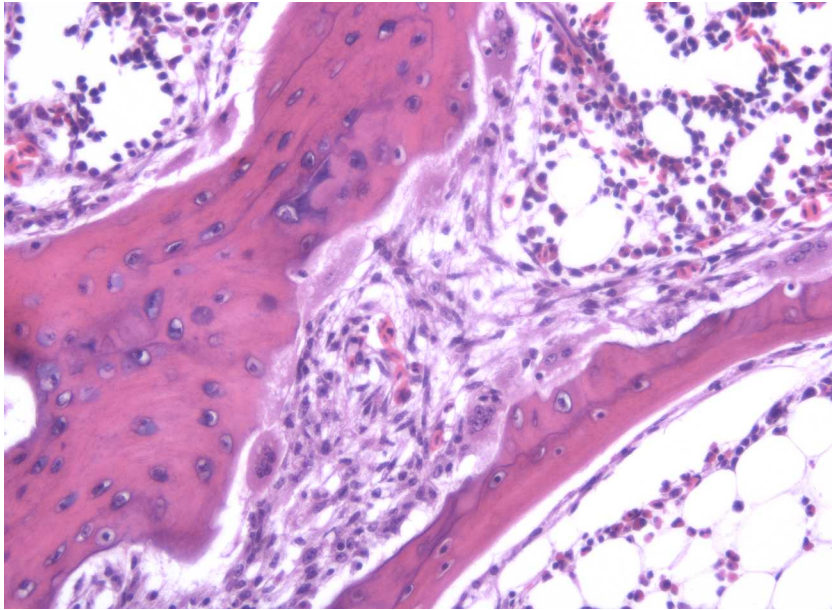


Figure 18. Medullary bone from the tibiotarsus of the grey parrot in figure 16. The trabeculae have markedly irregular margins lined by increased numbers of osteoclasts. (Haematoxylin and eosin, 200X).

vitamin D₂ (ergocalciferol) was less efficient than vitamin D₃ (cholecalciferol) in preventing rickets in poultry (McChesney E.W. 1943). Since the 1940s cholecalciferol has been used to supplement poultry foods in order to prevent leg abnormalities. In the 1960s the metabolic route of cholecalciferol to the active metabolite 1,25 dihydroxycholecalciferol via 25 hydroxycholecalciferol was revealed. Since this discovery, defects of metabolism of cholecalciferol or the different biopotency of individual vitamin D₃ supplements used in the diets have been suspected in the development of leg abnormalities (Olsen W.G. & others 1981, Bar A. & others 1987, Yang H.S. & others 1973). It has been demonstrated that 1,25 dihydroxycholecalciferol is 2-4 times more active than cholecalciferol in growing chickens (Boris A. & others 1977). Edwards (1989) confirmed that supplementation with 1,25 dihydroxycholecalciferol proved significantly more effective than cholecalciferol in reducing the incidence of tibial dyschondroplasia in broilers. It has been postulated that fast growing chickens are unable to metabolise cholecalciferol to 1,25 dihydroxycholecalciferol efficiently enough to allow adequate calcium absorption and bone formation (Xu T. & others 1997). Subsequently the relative efficacy of the vitamin D₃ metabolites in preventing tibial dyschondroplasia has been elucidated (Edwards H.M. Jr. 1990). Ultraviolet light supplementation allows vitamin D₃ synthesis, equivalent to 20ug/kg of dietary supplementation (Edwards H.M. Jr. & others 1994). Tibial dyschondroplasia cannot be prevented by the provision of ultraviolet light (Mitchell R.D. & others 1997a).

Fat-soluble vitamins compete for the same binding sites; therefore a dietary excess of one individual vitamin will potentially lead to a deficiency in the others. Diets containing excessive vitamin E (greater than 1000mg/kg diet) increase the requirement for vitamin D₃ (Murphy T.P. & others 1981). Over the last decade, vitamin E levels in poultry diets have been increased in order to improve fertility (Surai P.F. 2002). However, a moderate dietary excess of vitamin E (150mg/kg) has not been shown to cause cholecalciferol deficiency (Bartov I. 1998). Both a lack and an excess of vitamin A has been shown to cause leg abnormalities in chickens and turkey poults (Howell J.M. & Thompson J.N. 1967, Tang K. & others 1984).

2.11.4 Evaluation of avian bone and its response to metabolic bone disease

Avian bone is a complex metabolically active tissue subject to continuous turnover during adult life (Loveridge N. & others 1992). Traditionally in man evaluation of the skeleton involves plain radiography combined with advanced imaging techniques including computed tomography, magnetic resonance imaging, nuclear scintigraphy and bone densitometry. These techniques have the disadvantage of recording past skeletal activity rather than rate of bone turnover at the present time (Allen M.J. 2003). Biochemical biomarkers of bone metabolism, which indicate a real time evaluation of bone metabolism, are being used increasingly in man, The biomarkers specifically indicate either bone resorption or bone formation activity providing a non-invasive tool for monitoring therapy of metabolic bone disease (Ravin P. & others 1999). They can be measured rapidly and inexpensively in either serum or urine. The biochemical marker assays have already been used in animals investigating animal models of human disease. The effects of age on bone formation and bone resorption in horses and dogs has been reported (Price J.S. & others 1995, Allen M.J. & others 1998). Unfortunately there are no commercial bone biomarkers available for poultry as they could provide an important non-invasive method for evaluating juvenile osteodystrophy in grey parrots and the response of the skeleton to medical or surgical intervention.

Bone densitometry is accepted as a useful quantitative measurement for assessing skeletal status in man (Miller P.D. & others 1996). Low bone mass measurements are as useful a predictor for fracture susceptibility as are high cholesterol or high blood pressure measurements predictors for myocardial infarction or stroke respectively (The WHO Study Group, 1994). The use of bone density measurements is used to evaluate tibial strength in poultry. There is a significant correlation between bone density and tibial breaking strength ($r^2=0.62$). Bone density measurements are more convenient as they do not require bone cleaning prior to measurement (Frost T.J. & Roland D.A. Sr. 1991).

Hounsfield introduced Computed Tomography (CT) scanning for medical imaging in the early 1970s, based on mathematical principles developed by Radon in the late nineteenth century. Computed Tomography scanning enables a cross-sectional image of an object to be generated through mathematical folding of absorption profiles of numerous x-ray

beams projected onto it from different angles (a method called filtered back-projection). The principles and application of CT imaging in zoo and wildlife medicine has been reviewed (Spaulding K. & Loomis M.R. 1999). Peripheral Quantitative Computed Tomography (pQCT) is capable of determining bone mineral density (BMD) through calibration with phantoms of known mineral density, geometrical parameters and soft tissue distribution (Guglielmi G. 2002). It is the only available method for the determination of the true volumetric density (Ibanez R., 2003).

2.12 Biology of grey parrots

The grey parrot (*Psittacus e. erithacus*) is widespread in equatorial Africa. It is the second most commonly traded psittacine bird in the world pet trade, desired mainly for its excellent mimicry. Despite this there are limited studies available on their natural behaviour including the natural diet. The annual average export from Africa is 47,357 birds. There are 2 subspecies recognised. *Psittacus erithacus timneh* is found from Sierra Leone to the Ivory Coast with isolated populations in Guinea-Bissau and South Mali. *Psittacus e. erithacus* is found from the southeastern Ivory Coast to western Kenya. It is also found in Northern Angola, southern regions of Zaire and to northwestern Tanzania. *Psittacus erithacus timneh* may be a separate species as little interbreeding occurs between the two subspecies. The birds measure 28-39cm from tail to cranium with a weight range of 402-490g. The head has a white bare facial area around the eye. Light grey feathers extend over the head to darker grey feathers on back and breast. The wings are mid grey with blackish grey primaries. The tail and tail coverts are bright red. The timneh subspecies is generally smaller, darker and possesses a dull red tail. The main habitat is both primary and secondary lowland moist forest including the edges and clearings. The birds have been found on mangrove swamps and cultivated land. Although grey parrots visit savannah woodland to feed they are mainly found in lowland tropical forests. They congregate in large flocks generally preferring very tall trees for roosting and feeding. A typical roosting site would be a raphia palm fringing a river. The flexibility of raphia palm branches and the border of water are thought to reduce the risk of nocturnal predation. Grey parrot roosts are traditional and if left undisturbed by trappers may remain in use for

decades. The natural diet comprises of seeds, nuts, fruits and berries obtained from the top of the tree canopy. They are known to prefer palm oil fruits (*Elaeis guinensis*) but do not eat the stone. They have been known to perform geophagy in forest clearings and quartz has been found in the stomach contents of these birds. The birds breed from November to April in West Africa; June to July in East Africa: July to December in Zaire. They nest in holes in tall trees such as *Terminalia seperba*, *Ceiba pentandra* or *Distemonanthus benthamianus*. The nests are normally solitary. Two to three eggs are laid per clutch. The incubation period is 21-30 days with the birds leaving the nest after around 80 days (Collar N.J. 1997).

2.13 Nutrition of captive psittacine birds

2.13.1 Introduction

Chronic malnutrition is a common clinical presentation in captive parrots with most pet parrots presenting with multiple nutrient deficiencies or excesses rather than problems with a single dietary component (Roudybush T.E. 1999, Roudebush P. 2000). Although parrots can survive on seed mixes, they are chronically malnourished and unhealthy with poor reproductive performance (Schoemaker N.J. & others 1999). Commercial seed based parrot foods are frequently multi-deficient for the needs of the larger psittacine birds (figure 19). Psittacine birds are often classified as purely seed eaters despite studies indicating a great diversity of food materials taken in the wild. Although seeds are consumed in their natural habitat so are flowers, buds, leaves, fruits and cambium (Koutsos E.A. & others 2001). Traditionally, diets were based on the anecdotal information of aviculturists and the limited field observations of ecologists. More recently, however, by establishing research populations of captive parrots, scientists have been able to produce valid, quantitative information about the nutritional requirements of these birds. However, parrot diets are still mostly based on the standard nutritional requirements for poultry and will be for the



Figure19. Traditional seed mix. Although this type of seed mix is imbalanced and encourages selective feeding it is still the most common diet used by aviculturists in the UK.

foreseeable future. Despite distinct differences in both functional digestive anatomy and life style between commercial poultry and captive psittacine birds, the nutritional requirements for poultry derived by the National Research Council (NRC 1994) are still considered to be the standard for predicting the nutritional requirements of parrots. An adaptation was adopted by the Association of Avian Veterinarians (AAV) in 1996 as a guide-line for developing formulated parrot diets, recommending maintenance needs for adult birds. Recent published research indicates that the optimal diet for pet parrots is one based on a complete, balanced formulated product with limited seed and human food supplementation (Hess L. & others 2002). It has been shown that parrots fed diets consisting of less than 50% balanced formulated food risk deficiency of several vitamins and minerals, particularly vitamin A, vitamin E and calcium. However, the majority of psittacine birds are still fed parrot seed mixes promoted by the pet trade, which are usually both nutritionally inadequate, and of poor quality (Robben J.H. & Lumeij J.T. 1989). Although nutritional problems are common in all psittacine birds, grey parrots, cockatoos and cockatiels are most frequently represented (Stanford M.D. 2005b). This is probably because they are the parrots most likely to resist changes to their diet. They are also the birds most likely to become obsessed with individual food components. The main benefits of feeding a formulated diet become obvious when the feeding of captive birds is compared with the feeding of other companion animals. The use of commercially prepared diets has contributed markedly to improved health in companion pets over the last 30 years and this would be expected to be the case in the future with captive parrots.

The nutritional requirements of poultry vary with their physiological state and, despite lack of research; it is reasonable to assume that this would be the case with parrots too. It is already known that during the breeding season many species of parrots supplement their diet with insects in order to increase their dietary calcium and protein. Growth, moulting and reproductive activity would all be expected to affect the requirements for nutrients, as would severe disease. Laying females have an increased requirement for calcium; their diet must also not contain excessive phosphorus. The increase in calcium requirement is not excessive compared with production poultry. For example cockatiels will produce well-

shelled eggs on 0.85% dry matter calcium (compared with 0.5% for maintenance). It is also important to ensure that vitamin D₃ levels are adequate for correct calcium homeostasis.

The rapid skeletal growth experienced by psittacine chicks results in an increased requirement for calcium but, surprisingly, this is not excessive (1% appears sufficient). The correct vitamin D₃ content, however, is essential and failure to provide sufficient would be expected to cause osteodystrophy in young psittacine chicks.

Geophagy, the consumption of soil, is widespread in vertebrate animals especially herbivores (Jones R.L. & Hanson H.C. 1985, Mahaney W.C. & others 1996). It is also reported in reptiles (Sokol O.M. 1971, Marlow R.W. & Tollestrup K. 1982), and in many seed-eating birds (Pendergast B.A. & Boag D.A. 1970, Munn C.A. 1992, Pryce E. 1994, Gionfriddo J.P. & Best L.B. 1995). The function of geophagy is undetermined but there are several hypotheses including mechanical enhancement of the digestive tract and the release of minerals to supplement inadequate nutrition. Soil may buffer intestinal pH allowing vitamins and minerals to be more efficiently absorbed. Finally the clay may reduce the toxicity of a diet either by altering mucous secretion in the intestine or by reducing the toxicity of certain plant foods. A recent extensive study of geophagy in Amazona species by Gilardi and others (1999) demonstrated that the main function of geophagy in this species was protection of the intestinal wall from toxins and an overall decrease in the toxicity of plants.

Psittacine birds are unable to synthesise most of the vitamins they require, so these have to be supplied in the diet. Unfortunately, over-supplementation with multi vitamin mixtures is a common practise in aviculture that can lead to either hypervitaminosis or secondary hypovitaminosis. This is particularly true for vitamins A and D₃ (Koutsos E.A. & others 2001). Fat-soluble vitamins can be stored indefinitely in birds and this can lead to problems with toxicity, especially of vitamins A and D₃ in over-supplemented birds. As fat-soluble vitamins compete for the same lipid binding sites, the correct vitamin balance is vital as an excess of one fat-soluble vitamin can lead to a deficiency in another (Abawi F.G. & Sullivan T.W. 1989). Carotenoids (provitamin A) also compete for binding sites with the fat-soluble vitamins so a dietary excess of fat-soluble vitamins may also lead to carotenoid deficiencies (Surai P.F. & others 1998). Vitamin instability, together with varying water

intake, suggests that it is not advisable to supply vitamins in the water. Although it is possible to fortify seeds with minerals, vitamins and essential amino acid coatings, it is difficult to create a balanced diet as seeds are rapidly dehusked when eaten. It is better to attempt to provide sufficient in the diet instead. There are 13 minerals essential for the optimum health of parrots but, with the exception of calcium, research is lacking into specific mineral activity and requirement. High levels of the macrominerals calcium, phosphorus, magnesium, sodium, potassium and chloride are essential, whereas the trace minerals zinc, copper, iodine, selenium, iron and manganese are only required in low concentrations (Klasing K.C. 1998). The availability of minerals is dependent not only upon their concentration in food but also upon many other factors such as the chemical form of the mineral (for example, selenium has 4 valent forms, all with different chemical activity) and the level of other minerals in the food (for example, high phosphorus levels will reduce calcium absorption). Deficiencies and toxicities of minerals are usually prevented as the intestinal tract is designed only to absorb minerals according to need.

2.13.2 Calcium

Clinical problems associated with calcium metabolism affect all psittacine birds especially grey parrots. It is vital to consider calcium homeostasis as a whole, taking into account UVB (285-315nm) light levels, dietary calcium and vitamin D₃ when evaluating clinical cases showing signs suggestive of calcium metabolism disorders.

Calcium is the most prevalent mineral in the adult bird constituting over 30% of the total mineral content. It is required at higher levels in the diet than any other mineral. The skeleton acts as a reservoir of calcium containing 98% of a bird's total body calcium mainly in the form of hydroxyapatite ($\text{Ca}_{10}(\text{PO}_4)_6(\text{OH})_2$). Calcium requirements vary in birds depending on physiological state. It is greatest in the egg laying bird and in the growing chick. At maintenance only small amounts of dietary calcium are required to replace losses through urine and faeces. This is thought to be less than 0.2% in adult chickens. During growth the requirement for calcium is highest at the start of life decreasing as full adult size is reached. Calcium requirement in chickens is significantly affected by the growth rate of the birds (Hurwitz S. & others 1995). Altricial birds such as grey parrots would be expected

to have greater requirements than precocial birds due to greater growth rates and poor calcification of the skeleton at birth. Unfortunately the increased requirement has not been evaluated to date. Birds frequently supplement youngsters' diets with food materials with a higher calcium concentration such as insects, molluscs and bone fragments (Graveland J. & Van Gijzen T. 1994). During egg laying the increased calcium requirement depends on clutch size and frequency in addition to the amount of calcium deposited in the shell. Small birds have a higher calcium requirement as they lay proportionately larger eggs than bigger birds. Precocial species have a higher calcium requirement than altricial birds due to producing larger eggs. The majority of the calcium for the shell is obtained from medullary bone formed in the weeks before egg production so any increase in calcium requirement is spread over a period of time. The calcium requirement of a laying hen is between 2.25-3.25% for continuous egg production. In comparison an altricial species, the cockatiel, has been shown to have a lower requirement between 0.35-0.85% for calcium whilst still producing large numbers of normal eggs (Earl K.E. & Clarke N.R. 1991, Roudybush T.E. 1996). It has been suggested that in budgerigars a high dietary level of calcium (greater than 0.7%) is responsible for metastatic calcification of the kidney independent of dietary vitamin content (Roset K. & Phalen D.N. 2000).

The calcium content of seeds traditionally fed to psittacine birds is low (less than 0.1%). Seeds also contain high levels of phosphate in the form of phytic acid, which can complex with calcium in the intestine thereby preventing adequate calcium absorption (Kratzer F.H. & Vohra P. 1986).

Calcium deficiencies can occur due to low dietary calcium, inadequate vitamin D₃ supplementation or excessive dietary phosphorus. In all cases the deficiency is known as nutritional secondary hyperparathyroidism. Clinical signs range from skeletal abnormalities to tetanic seizures.

In wild bird populations calcium deficiencies can regulate reproductive success. Great tits (*Parus major*) rely on calcium from snail shells for egg formation. If this source is removed then reproductive success falls due to poor egg shell formation and subsequent embryonic death (Drent P.J. & Woldendorp J.W. 1989, Gravelan J. 1996). Cape vulture chicks suffer from rickets if access to bone fragments is denied (Richardson P.R.K. & others 1986).

Free-living Indian rose ringed parakeets (*Psittacula krameri*) have been shown to breed when food material with extra nutrients (including calcium) is available for eggshell production (Sailaja R. & others 1988).

The absorption and excretion of phosphate and calcium is interdependent. The dietary calcium to phosphate ratio is therefore important and calcium to phosphate ration of 2:1 (as in bone) is considered optimal for birds. Many seed diets contain sub-optimal ratios often as high as 1:37 (Arnold S.A. & others 1973). This would certainly be considered a factor in the development of nutritional secondary hyperparathyroidism in grey parrots.

2.13.3 Phosphate

Phosphate is mainly found in bone (85%) in birds but also occurs as phospholipids, nucleic acids and adenosine triphosphate. Absorption from the intestine is controlled by 1, 25 dihydroxycholecalciferol. Most food materials of animal origin are good sources of bio available phosphate whereas seeds are considered deficient because the phosphate in seeds is frequently found as phytic acid. Phytic acid requires the presence of phytases in the intestine to liberate the phosphorus (Pallauf J. & Rimbach G. 1997). Phytases are only found in limited amounts in birds so phosphorus is not considered biologically available in this group. The phosphate requirement in adult chickens for maintenance is approximately 0.1% (with a dietary calcium content of 0.2%). This is less than that required by a growing chick. Chicks fed diets high in phosphate have a higher incidence of hypocalcaemic rickets and tibial dyschondroplasia (Williams B. & others 2000). There is an increased phosphate requirement in egg laying birds. This is due to increased renal excretion of phosphate from the bone mobilised to provide calcium for the eggshell production rather than for use in egg formation (Wideman R.F. 1987, Clunies M. & others 1992).

Phosphate deficiency in growing chicks leads to slow growth rates with poor bone mineralisation. Severe deficiencies can cause rickets and sudden death. Phosphate deficiency in egg laying birds reduces both egg numbers and fertility rates. Most diets fed to captive poultry and to psittacine birds are based on cereals containing phosphate in the non-bioavailable phylate complex. These diets must be supplemented in order to prevent phosphate deficiency (Cain J.R. & others 1982). Diets low in phosphate stimulate an

increase in plasma concentrations of ionised calcium and 1,25 dihydroxycholecalciferol, but higher dietary phosphate levels suppress this response, leading to calcium deficiency (Frost T.J. & Roland D.A. Sr. 1991).

2.13.4 Vitamin D₃

Vitamin D₃ was traditionally classed as a fat-soluble vitamin. It is now classified as a steroid hormone. It is supplied via the diet or by endogenous synthesis from vitamin D₃ precursors requiring UVB light. The same pathways as fatty acids and cholesterol absorb it with 2% dietary fat required for adequate absorption. The vitamin can be stored and excesses excreted. Despite this, vitamin D₃ deficiency and toxicity is relatively common in birds. Vitamin D₃ is toxic if supplied in excessive levels in the diet as it causes mobilisation of calcium from the bone creating hypercalcaemia, soft tissue calcification and finally renal failure. Vitamin D₃ toxicity has been induced in macaws at lower dietary levels than in other species (1000IU/Kg). This suggests that vitamin D₃ metabolism varies between psittacine species. Poultry fed excessive vitamin D₃ use the egg as an excretion vehicle, leading to embryonic death. It would perhaps be sensible to feed parrots a formulated diet with vitamin D₃ concentrations close to the poultry requirements, ensuring adequate UVB light to prevent vitamin D₃ toxicity problems. Cholecalciferol is normally used to supplement poultry diets with vitamin D₃ as it has to be metabolised prior to activity. This reduces problems with toxicity with the other metabolites especially 1,25 dihydroxycholecalciferol, which does not support normal embryo development (Soares J.H. & others 1995). In addition cholecalciferol has been shown to be more effective than 1,25 dihydroxycholecalciferol in preventing bone lesions associated with vitamin D₃ deficiency (Cheville N.F. & Horst R.L. 1981). The toxicity of cholecalciferol and 25 hydroxycholecalciferol has been studied in chicks (Morrissey R.L. & others 1977). 25 hydroxycholecalciferol has been used in poultry feeds to prevent leg abnormalities with apparent safety at 82.5 -412.5 micrograms/kg feed (Terry M. & others 1999, Baker D.H. & others 1998). Dietary supplementation with cholecalciferol is unlikely to cause toxicity signs as it requires hydroxylation into active metabolites. Serum concentrations of 25 hydroxycholecalciferol increases more rapidly in chicks fed 25 hydroxycholecalciferol

compared with cholecalciferol supplemented diets (Yarger J.G. & others 1995). Cholecalciferol is unstable during the storage and manufacture of diets so it is usually added at 3-10 times the requirement.

Poultry do not have a requirement for vitamin D₃ if they receive adequate radiation in the 285-315nm spectra. In growing poultry chicks it has been shown that 11-30 minutes daily of strong sunshine prevents vitamin D₃ deficiency. As most domestic poultry and captive parrots are kept indoors they are prone to vitamin D deficiencies unless fed a diet with adequate vitamin D₃ or supplied artificial UVB light. Vitamin D₃ shares the same receptors as vitamins A, E and K so an excess of any of these vitamins can create a vitamin D₃ deficiency due to receptor displacement. Vitamin A toxicity can induce osteodystrophy in broilers with parathyroid hypertrophy (Tang K. & others 1984). The interactions between dietary levels of vitamin A, vitamin E and cholecalciferol have been extensively researched by Aburto and Britton (1998a, 1998b). The results demonstrate the need for creating diets with proper ratios of vitamin A, D₃ and E (Aburto A. & others 1998). Vitamin A deficiency has traditionally been thought to be a common disorder in psittacine birds but recent work has demonstrated that cockatiels (*Nymphicus hollandicus*) have a maintenance requirement of just 2000IU/kg (Koutsos E.A. & others 2003). The clinical signs of vitamin A deficiency mimic those for toxicity so many captive psittacine birds may be misdiagnosed. This may create a secondary vitamin D₃ deficiency. In conclusion, hypocalcaemia or vitamin D₃ deficiencies are still common in aviculture especially in the grey parrot. Formulated diets containing adequate vitamin D₃ and calcium should prevent the clinical signs of disease (Ullrey D.E. & others 1991)

The following research studies calcium metabolism in grey parrots. It investigates the effects of feeding diets with different vitamin D₃ and calcium content on blood concentrations of ionised calcium, 25 hydroxycholecalciferol and parathyroid hormone in healthy adult grey parrots. In addition the effects on calcium metabolism of providing ultraviolet light to captive grey parrots are established. These results are compared with data from a South American species (*Pionus spp.*) of parrot and wild grey parrots. Finally clinical cases of hypocalcaemia in grey parrots are investigated to confirm that the

disorders of calcium metabolism seen in the grey parrots are due to nutritional secondary hyperparathyroidism.

CHAPTER 3

Methodology

The effects of staged changes in husbandry on calcium metabolism in a group of 40 healthy adult grey parrots (*Psittacus e. erithacus*) from a private collection were investigated over a period of three years. The results from the main study were compared with similar parameters measured in a group of wild grey parrots and a group of captive healthy South American parrots (*Pionus spp.*). Separate studies assessed clinical cases of hypocalcaemia and juvenile osteodystrophy in grey parrots presented at the author's practice.

3.1 Main population

The main population comprised of 100 healthy sexually mature grey parrots housed indoors as 50 pairs. All the birds had been wild caught, exported from Guyana, and purchased from a single source in 1999. Prior to purchase each bird in the main population had been clinically examined using a standard protocol. Faecal samples were submitted for parasitology, microbiology and Gram stain examination. Blood samples were subjected to routine haematological and biochemical analysis including circovirus, polyomavirus and chlamydia PCR testing. Each bird was examined by laparoscopy to confirm sexual maturity and gender. On the basis of these tests only healthy adult birds were included in the main population. A total of 297 birds were examined to produce the healthy group of 100 birds. Each pair was housed in an identical breezeblock and wire aviary measuring 2m by 2.5m. Each aviary had a wooden shoebox design nest box measuring 40cm by 30cm. All the aviaries were positioned in a single span windowless farm building of brick and slate roof construction with no exposure to natural ultraviolet light. The birds were fed a seed based diet (Figure 20, Tidymix TM, John Heath, Hull, UK, see Table 1) without additional vitamin or mineral supplementation. Water was supplied *ad libitum*. The birds had been kept under these husbandry conditions for 18 months prior to the commencement of the study. Every 12 months the birds were clinically examined and blood samples analysed as part of an annual health examination requested by the owner.



Figure 20. Seed mix used in the main study (Tidymix TM Diet).

3.2 Study design

40 birds were selected from the main population using a simple randomisation process to form the study group. These birds were randomly allocated into 2 groups of 10 pairs of grey parrots (n=20 birds per group: 10 male and 10 female). These birds were kept in the same building under the same conditions as the main population. During the annual health examination additional blood was taken from the study group in order to investigate calcium metabolism in grey parrots with the informed consent of the owner.

During the first 12 months of the study all 40 birds were fed the seed mix (Tidymix) traditionally fed by the owner to all psittacine birds on the premises with no additional vitamin or mineral supplementation. During the annual health examination the blood samples taken under isoflurane anaesthesia were assayed for ionised calcium, 25 hydroxycholecalciferol and parathyroid hormone, in addition to a standard haematological and biochemical health profile (Table 2).

In the second year of the study one group was maintained on the original seed diet to act as a control group and the other group was transferred onto an unsupplemented formulated parrot diet (Figure 21, High Potency Organic formulated diet TM, Harrison's Bird Diets, HBD Int., Nebraska, USA.). Dietary analysis was performed by The Royal Veterinary College, Hawkshead, UK (Table 1). The birds were fed standard amounts of either diet daily rather than being provided food *ad libitum* in an attempt to prevent selective feeding in the seed diet. No other changes were made in the group's husbandry during the second year. Blood sampling was repeated after a further 12 months, again as part of the annual health examination, to assess the effect of the dietary changes on the ionised calcium, 25 hydroxycholecalciferol and parathyroid hormone levels.

Ingredient	Tidymix seed	Harrison's High Potency Course Pellet
Crude Protein (%)	15.33	20
Crude Fat (%)	17.39	12
Crude Fibre (%)	5.25	5
Crude Ash (%)	2.2	3.2
Moisture (%)	27.01	10
Calcium (%)	0.08	0.9
Phosphorus (%)	0.38	0.4
Calcium/Phosphorus ratio	0.21	2.25
Vitamin A (IU/Kg)	1450	11000
Vitamin D (IU/Kg)	0.00	1650
Vitamin E (mg/Kg)	599.9	450

Table 1 As fed analysis of diets used in study

Parameter	Reference range ¹
Pack Cell Volume (PCV)	45.0-53.0%
Red Blood Cell Count	3.0-3.6 x 10 ¹² /l
Total White Blood Cell Count	6.0-13.0 X 10 ⁹ /l
Heterophils	4.27-6.93X 10 ⁹ /l
Lymphocytes	1.8-4.8X 10 ⁹ /l
Monocytes	<1.9X 10 ⁹ /l
Eosinophils	< 0.85X 10 ⁹ /l
Basophils	<0.85X 10 ⁹ /l
Ionised Calcium	0.96-1.22mmol/l
Total Protein	27.0-44.0g/l
Albumin	9.0-18.0g/l
Globulin	12.0-36.0g/l
ALP	24-94IU/l
Bile Acids	18-80 umol/l
Total Calcium	1.65-2.68mmol/l
Magnesium	mmol/l ²
Phosphorus	1.00-3.40mmol/l
Uric Acid	100-500umol/l
25 hydroxycholecalciferol	nmol/l ²
Parathyroid Hormone (PTH1-34N)	pg/ml ²

1 Stanford M.D. 2002c.

2 No reference range published for grey parrots.

Table 2 Standard blood health profile performed on each bird



Figure 21. Pellet diet used in main study (Harrison’s High Potency Course TM diet).

In the third year of the study all the birds were placed under artificial ultraviolet light (UVB 315-285nm) for 12 hours each day with the diets remaining unchanged. The UVB light was supplied via paired 1200mm 36W FB36 Arcadia bird lamps (Arcadia, Arcadia House, Cairo New Road, Croydon, UK) suspended directly above each aviary. Perching birds would be a maximum distance of 0.5 metres from the tubes. A reflector (Arcadia ALR36) was mounted behind each tube to direct light towards the birds maximising the amount of UVB that each bird received. An Elsec UVB light monitor 763 (Littlemoore Scientific Engineering, Railway Lane, Oxford UK) was used to demonstrate the increase in ultraviolet light levels experienced by all the birds in the third year. The monitor uses two photodiodes, which detect UVB radiation in the 285-400nm wavelengths expressed as mW/m^2 . The tubes were replaced after 6 months according to the manufacturers instructions. Further blood tests were taken during the annual health examination, following 12 months exposure to UVB light, to assess the effects of UVB radiation on calcium status in grey parrots.

3.3 Blood analysis

3.3.1 Handling of blood samples

The blood testing was performed on September 1st each year outside the UK breeding season to minimise the potential effects of both oestrogen and seasonality on both vitamin D3 and calcium levels (Bentley P.J. 1998). A 2ml blood sample was taken from each bird using the brachial vein, under isoflurane anaesthesia. This was divided equally into heparin and EDTA Eperndorph [™] tubes. The EDTA sample was centrifuged for 15 minutes at 1600/rpm and the plasma decanted into another eperndorph tube. The plasma sample was immediately cooled to -70°C for subsequent analysis for parathyroid hormone.

3.3.2 Biochemical analysis

Routine biochemical analysis of the heparinised serum sample was performed using a SPACE [™] wet chemistry analyser (Randox LTD) within 12 hours of sample collection. This analyser uses standard spectrophotometer methodology. The analyser was calibrated every 24 hours. Albumin concentrations were measured using serum protein

electrophoresis due to known problems with avian protein evaluation (Lumeij J.T. & others 1989). Haematological analysis was performed manually.

Ionised calcium, sodium and potassium concentrations were determined using an AVL 9181 analyser within 30 minutes of venepuncture in order to avoid potential problems associated with any delay on electrolyte assays. The methodology employed by the analyser is based on the ion selective electrode (ISE) measurement principle to precisely determine ion values (Stanford M.D. 2001). The analyser is fitted with three ISE electrodes for ionised calcium, potassium and sodium assay. Each electrode has an ion selective membrane that undergoes a specific reaction with the corresponding ions contained within a particular sample. The membrane is an ion exchanger, which reacts to the electrical charge of the ion, and this causes a change in the membrane potential or measuring voltage, which is built up between the membrane and the sample. A galvanic measuring chain within the electrode determines the difference between the potential values on either side of the membrane of the active electrode, and a highly conductive, inner electrode to an amplifier conducts the potential. The ion concentration is then determined using a calibration curve produced by measuring the potentials of standard solutions with a precisely known ion concentration (Stanford M.D. 2001). The AVL 9181 analyser was calibrated every 24 hours.

The IDS OCTEIA 25 hydroxycholecalciferol kit (IDS Ltd. 10 Didcot Way, Tyne and Wear, Newcastle upon Tyne) was used in this study for the quantitative determination of 25 hydroxycholecalciferol. The kit is an enzyme immunoassay for the quantitation of 25 hydroxycholecalciferol in serum and plasma. Samples were diluted with biotin labelled 25 hydroxycholecalciferol and incubated in microtitre wells coated with highly specific sheep 25 hydroxycholecalciferol antibody for 2 hours at room temperature. Horseradish Peroxidase labelled avidin was added which binds selectively to the complexed biotin. After washing colour was developed using a chromogenic substrate. The absorbance of the stopped reaction mixture was read using a microtitre plate reader: the colour intensity being inversely proportional to the concentration of 25 hydroxycholecalciferol. Two control samples provided in the kit were tested independently for quality control. The kit has been

tested for accuracy against a recognised radioimmunoassay with significant correlation results ($r=0.91$). Each sample in the study was assayed in duplicate.

Parathyroid hormone (PTH) was assayed using a 1-34 PTH (rat) research kit because of the problems associated with a commercial intact 1-84 PTH assay in grey parrots. The PTH 1-34 enzyme immunoassay used was a competitive enzyme immunoassay kit specifically designed to detect PTH 1-34 (Peninsula Laboratories 601 Taylor Way, San Carlos, California 94070). PTH 1-34 peptide was extracted using a C18 separation column extraction technique. For the assay PTH 1-34 peptide antibody, biotinylated PTH 1-34 peptide and the sample were placed in an immunoplate well. The PTH 1-34 antibody binds to the walls of the wells and the biotinylated PTH 1-34 peptide competes for antibody binding sites with the non-biotinylated PTH 1-34 peptide in the sample. Following incubation unbound biotinylated PTH 1-34 peptide was removed by washing. Streptavidin-conjugated Horseradish Peroxidase was added. This binds with the PTH 1-34 peptide antibody- biotinylated PTH 1-34 peptide complex. After a further wash 3,3',5,5'-Tetramethyl Benzidine Dihydrochloride was added, which reacts with Horseradish Peroxidase to produce a colour change. The colour intensity is proportional to the quantity of biotinylated PTH 1-34 peptide bound to the PTH 1-34 peptide. A microplate reader was used to read the colour absorbencies at 450nm. A ten point standard curve was plotted using standard peptide PTH 1-34 supplied with the assay. Unfortunately it was not possible to routinely use this assay in all clinical cases due to the large sample size required for the birds (1ml whole blood volume per assay) and complexity of the assay.

3.3.3 Progeny testing

Progeny ($n=19$), all parent reared, from the group of 40 adult birds produced over the three year study period were examined at 8 weeks of age as part of a routine post purchase examination. The examination included a ventral-dorsal and lateral radiograph under isoflurane anaesthesia to look for evidence of osteodystrophy. Each radiograph was taken using Fuji Mammography film and cassettes at identical exposures. A marker bone from a mature grey parrot was used on each film so allowances could be made for both

developing and exposure discrepancies (fig 22 & 23). The radiographs were examined by independently by three veterinary surgeons employed at the author's practice.

3.4 Wild parrots

Twenty wild grey parrots were trapped and blood samples taken within three days of capture. The blood was obtained for routine circovirus testing prior to export. In addition blood was analysed for ionised calcium and 25 hydroxycholecalciferol concentrations with the informed consent of the owner. A limited blood sample size could be obtained from the wild greys in the field so routine biochemical and haematological analysis was not possible. The birds were, however, considered healthy on the basis of clinical examination by the attending veterinary surgeon.

It was not possible to assay blood for parathyroid hormone due to the limitations in blood storage in the field situation and the small volumes obtained. There was also a delay of 72 hours after venepuncture before analysis could be performed.




Figure 22. Post purchase check ventral-dorsal radiograph on a juvenile grey parrot. This demonstrates the use of the standard marker bone.

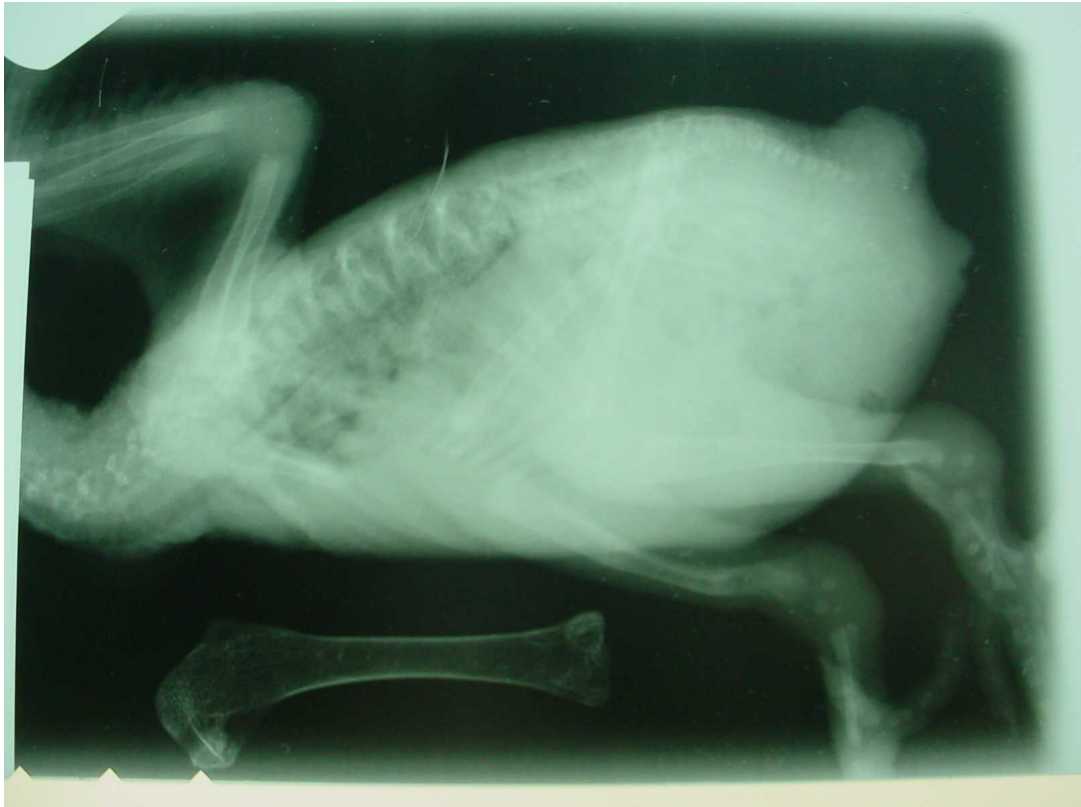

Figure 23. Post purchase check lateral radiograph of a grey parrot chick. This demonstrates the appearance of the marker bone on a radiograph to help standardise the interpretation of the films. This bird has evidence of osteodystrophy in the tibiotarsus.

3.5 Clinical cases

3.5.1 Hypocalcaemia in adult grey parrots

During the 3 year study 19 clinical cases of adult grey parrots exhibiting signs of hypocalcaemia were examined in the author's clinic. A full clinical history was obtained from the owner of each bird, including husbandry information. Blood samples from all the birds were analysed for ionised calcium and 25 hydroxycholecalciferol concentrations in addition to a routine biochemical and haematological profile as part of their standard investigation. Due to the severity of the clinical signs in most of these birds it was not feasible to assay blood for parathyroid hormone 1-34N because of the large blood volume required. All the birds were treated with a similar protocol. A calcium and vitamin D supplement, Zolcal™ (Vetark products), was administered twice daily by crop gavages. In addition they were given 12 hours supplementary UVB light provided artificially by Arcadia™ 2.4% fluorescent tubes and converted onto formulated pellet food (Harrison's High Potency Course). Five of these birds were monitored via 48 hour blood samples for ionised calcium until the plasma level returned to normal.

3.5.2 Juvenile osteodystrophy in grey parrots

Twelve juvenile grey parrots presenting at the practice with clinical evidence of osteodystrophy were included in the study with the informed consent of the owners. A full clinical history was taken including husbandry employed by the owner of the birds. It was noted whether the birds were hand or parent reared. A ventral dorsal and lateral radiograph was taken from these birds under anaesthesia and blood samples were assayed for ionised calcium and 25 hydroxycholecalciferol in these juvenile birds but not parathyroid hormone due to the large sample volume required for this assay. Surgical intervention and dietary management treated the majority of cases successfully but 3 birds were euthanased due to the severity of the lesions.

3.5.3 Histopathology and Computed Tomography (CT) of parrots

Dr Janet Paterson-Kane at The Royal Veterinary College examined pathological material from grey parrots with osteodystrophy. During the study 3 young grey parrots with clinical and radiographic evidence of osteodystrophy were euthanased on humane grounds between the age of 4 and 12 weeks old. Seven juvenile grey parrots were examined following euthanasia at the clinic for conditions not affecting the skeleton. Biochemistry results indicated calcium levels within the normal range (0.96-1.22mmol/l) in all these birds. Due to their age, the last four controls were excluded from histological analyses due to the absence of a growth plate in mature bones but were used for bone densitometry measurements.

Each bird was euthanased with intravenous pentobarbitone whilst anaesthetised with isoflurane. Each carcass was skinned. Humerus, radius, ulna, tibiotarsus and femur from the left side were dissected out and fixed in formal saline (10% v/v) prior to submission for histopathological examination. The contra lateral limb was frozen for histomorphus and bone densitometry procedures at a later date. The aim was to compare the results of the subjective histopathological examination with the more quantitative bone density measurements. All the major tissues, including parathyroid glands, were also submitted for histopathological examination to ensure the birds were suffering from no other illness apart from the osteodystrophy.

3.5.4 Histological method

Bones from the three euthanased control birds were decalcified in 10% formic acid (to allow for accurate sectioning). Their length was measured in millimetres and they were then transected at the midpoint. The proximal half of each bone was split coronally, with the dorsal and palmar halves processed routinely, and embedded in paraffin wax. Longitudinal sections were taken from the palmar half at a thickness of 4 μ m and stained with haematoxylin and eosin. Bones from the three birds euthanased with severe juvenile osteodystrophy were prepared similarly, however decalcification was not required and sections of the palmar half of the proximal end of each humerus were also stained by the Von Kossa method.

3.5.5 Quantitative histomorphometrical method

Digital images were taken at magnifications of 10X, 20X and 100X. Each image was calibrated using a stage micrometer and computerised image analysis was performed using Image Pro-Plus TM software version 4.5.1 (Media Cybernetics Inc., Silver Spring, Maryland, USA). The width of the epiphysis was measured and divided by total bone length. The lengths of the proliferative and hypertrophic zones of growth plate cartilage and the primary and secondary spongiosa were taken at 5 points across the epiphysis (at 20X magnification) and the mean value was then expressed as a proportion of total bone length. Bone spicules were counted for each section in three areas of interest at 100X magnification and the mean area was calculated using the manual polygon trace option on the Image-Pro Plus TM software. The mean osteoclast number in five separate areas of interest across the secondary spongiosa was calculated at 200X magnification. This work was performed by Dr Janet Patterson Kane, Royal Veterinary College, Hawkshead, London.

3.5.6 Peripheral Quantitative Computed Tomography (pQCT) method

The aim of this part of the study was to describe the histological lesions of metabolic bone disease in juvenile African Grey Parrots and to assess the viability of employing peripheral quantitative computed tomography (pQCT) as a diagnostic tool.

Analysis of the mean cortical and trabecular bone density and the area in which density thresholds are exceeded in each of the left tibiotarsi and humeri was conducted using an XCT2000 scanner (Stratec, Pharzheim, Germany) at two positions along the bone; the proximal end (at the level of the deltoid crest of the humerus and condyles of the tibiotarsus) and at 33% of the bone length distally from this point. At each position, a series of three tomograms, spaced at 1mm was produced at a voxel size of 0.2mm³. The translational scan movements were set at 10mm/sec (20mm/sec for the scout view).

The thresholds for cortical and trabecular bone density were determined as 257mg/cm³ and 180mg/cm³ respectively and were applied consistently throughout the analysis. The mean bone density and area for the three tomograms at each point was subsequently

calculated. The bone mineral density of the left tibiotarsus and humerus of three birds euthanased due to juvenile osteodystrophy were compared with 7 control birds.

Good Research Practice (GRP) guidelines were adhered to for all procedures and appropriate Control of Substances Hazardous to Health (COSHH) forms were completed. Mary Tyler BVSc, Royal Veterinary College, London on material supplied by the author, performed the bone density measurements.

3.6 Other psittacine birds

Bloods supplied by the author's supervisor Mr N.H. Harcourt-Brown from his own collection of South American parrots (*Pionus spp.* n=28, figure 24) were subjected to ionised calcium and 25 hydroxycholecalciferol analyses for comparison with the grey parrots. These birds were fed a pulse-based diet (Figure 25) with additional vitamin and mineral supplementation (Avimix TM, Vetark products, Winchester, UK). The main pulse diet was analysed by The Royal Veterinary College (Table 3). The birds were kept in a variety of aviaries in North Yorkshire with either no access to ultraviolet radiation or full exposure to natural sunlight. Blood samples were taken under isoflurane anaesthesia in August 2003 during endoscopic examination for sex determination. The birds were considered healthy on the basis of clinical, endoscopic examination and blood analysis.

The following year blood samples were taken from the same birds in March and August in order to assess the effects of natural ultraviolet light on vitamin D₃ metabolism in this species after concerns about skeletal development in the previous year.



Figure 24. A group typical of the South American birds used in the study (*Pionus spp.*).



Figure 25. Pulse based mix used to feed the South American birds in the study. The diet was supplemented with a vitamin and mineral mix (Avimix, Vetark Products, Winchester, UK).

Ingredient	Pulse mix
Crude Protein (%)	23.05
Crude Fat (%)	6.20
Crude Fibre (%)	8.10
Crude Ash (%)	4.20
Moisture (%)	23.46
Calcium (%)	0.29
Phosphorus (%)	0.33
Calcium/Phosphorus ratio	0.89
Vitamin A (IU/Kg)	3015
Vitamin D (IU/Kg)	185
Vitamin E (mg/Kg)	81.54

Table 3 As fed analysis of pulse diet used with South American birds

Statistical analysis

Professor Andrew Guppy-Adams independently advised the author on the statistical analysis of the quantitative data from the main study. The distribution of the data was analysed for normality initially to determine whether a parametric or non-parametric statistical test should be used to compare the variables. The Royal Veterinary College performed the statistical analysis on the histomorphological and bone densitometry data on the author's behalf. For all statistical tests a p value less than 0.05 was taken to indicate statistical significance.

CHAPTER 4

RESULTS

4.1 Main study group

4.1.1 Effects of dietary change on calcium metabolism

Table 4 shows the results for the first two years of the study demonstrating the effects of the change in diet on the blood calcium parameters. The seed fed group effectively acted as a control group for this part of the study. Shapiro-Wilk tests demonstrated that the data for ionised calcium, total calcium, 25 hydroxycholecalciferol and parathyroid hormone were not normally distributed for either the pellet or seed fed group during the first two years of the study.

The mean serum ionised calcium, total calcium and 25 hydroxycholecalciferol concentrations in the pellet fed group were found to be significantly greater 12 months after the dietary change using a Wilcoxon rank sum test. There was no significant changes in the serum ionised calcium, total calcium or 25 hydroxycholecalciferol concentrations in the seed fed group 12 months after the initial blood samples.

There was a statistically significant fall in the parathyroid hormone concentrations detected in the plasma in both the seed and pellet fed groups 12 months after the initial blood samples.

Table 4 Effect of dietary change on calcium parameters.

Parameter	Dietary Group	Mean +/- SD (Median) Year 1	Mean +/- SD (Median) Year 2	p value
Ionised calcium (mmol/l)	Seed	1.09 +/- 0.05 (1.08)	1.11 +/- 0.06 (1.10)	0.1227
	Pellet*	1.07 +/- 0.05 (1.08)	1.20 +/- 0.07 (1.19)	0.0001
Total calcium (mmol/l)	Seed	2.00 +/- 0.17 (2.08)	1.99 +/- 0.13 (1.97)	0.4669
	Pellet*	1.89 +/- 0.14 (1.89)	2.08 +/- 0.12 (2.04)	0.0013
25 hydroxycholecalciferol (nmol/l)	Seed	31.77 +/- 16.55 (23.60)	71.47 +/- 90.01 (35.25)	0.1743
	Pellet*	14.46 +/- 12.17 (11.40)	130.77 +/- 108.23 (118.40)	0.0001
Parathyroid hormone (pg/ml)	Seed	63.22 +/- 58.44 (26.00)	25.81 +/- 21.52 (18.90)	0.0160
	Pellet*	50.89 +/- 51.43 (26.00)	22.34 +/- 15.30 (19.05)	0.0095

* Group fed seed in year one then converted to pellet diet for year 2.

4.1.2 Effects of UVB supplementation on calcium metabolism

Table 5 displays the results at the end of the third year demonstrating the effect of UVB lighting on blood calcium parameters independent if the diet fed. Shapiro-Wilk W tests demonstrated that the data for ionised calcium, total calcium, 25 hydroxycholecalciferol and parathyroid hormone were not normally distributed in the third year of the study.

Mean serum ionised calcium, total calcium and 25 hydroxycholecalciferol concentrations in the seed fed group were found to be significantly greater 12 months after exposure to UVB lighting using a Wilcoxon rank sum test. There was a statistically significant increase in the serum ionised calcium and total calcium concentrations in the pellet fed group 12 months after exposure to UVB lighting using a Wilcoxon rank sum test. There was no significance difference in the serum 25-hydroxycholecalciferol concentrations in this group.

There was no significant change in the parathyroid hormone concentrations in either dietary group using a Wilcoxon rank sum test 12 months after exposure to UVB lighting.

Table 5 Effect of UVB lighting on plasma calcium parameters.

Parameter	Dietary Group	Mean +/- SD (Median) Year 2	Mean +/- SD (Median) Year 3	p value
Ionised calcium (mmol/l)	Seed	1.11 +/- 0.06 (1.10)	1.23 +/- 0.05 (1.24)	0.0001
	Pellet	1.20 +/- 0.07 (1.19)	1.24 +/- 0.06 (1.24)	0.0053
Total calcium (mol/l)	Seed	1.99 +/- 0.13 (1.97)	2.22 +/- 0.09 (2.22)	0.0001
	Pellet	2.08 +/- 0.12 (2.04)	2.22 +/- 0.10 (2.22)	0.0055
25 hydroxycholecalciferol (nmol/l)	Seed	71.47 +/- 90.01 (35.25)	139.66 +/- 69.22 (122.85)	0.0038
	Pellet	130.77 +/- 108.23 (118.40)	115.44 +/- 16.56 (112.85)	0.2753
Parathyroid hormone (pg/ml)	Seed	25.81 +/- 21.52 (18.90)	20.67 +/- 11.32 (16.80)	0.3124
	Pellet	22.34 +/- 15.30 (19.05)	19.23 +/- 7.36 (16.00)	0.5412

4.1.3 Comparison between dietary groups

Year 2 (12 months following dietary change)

Table 6 compares data between the two dietary groups using a Kruskal-Wallis one-way ANOVA test. There was a statistically significant increase in the serum ionised calcium, total calcium and 25 hydroxycholecalciferol concentrations in the pellet fed group compared with the seed control group. This demonstrates that feeding a diet with increased calcium and vitamin D₃ content significantly increases the serum concentrations of these parameters compared with feeding a diet with lower calcium and vitamin D₃ content. There was no significant difference in the parathyroid concentrations between the two groups 12 months after the dietary change.

Table 6 Comparison between dietary groups 12 months after the diet change

Parameter	Dietary group	Mean year 2	Kruskal Wallis ANOVA statistic	p value
Ionised calcium	Seed	1.11	11.28	0.0080
	Pellet	1.20		
Total calcium	Seed	1.99	2.90	0.0086
	Pellet	2.08		
25 hydroxycholecalciferol	Seed	71.47	4.21	0.0402
	Pellet	130.77		
Parathyroid hormone	Seed	25.81	0.08	0.7787
	Pellet	22.34		

Year 3 (12 months after UVB supplementation for both dietary groups)

Table 7 compares data between the two dietary groups in year 3 using a Kruskal-Wallis one-way ANOVA test after exposure to UVB lighting for 12 hours daily. There was no significance difference between the dietary groups in the ionised calcium, total calcium, 25 hydroxycholecalciferol and parathyroid hormone levels 12 months after the birds exposure to UVB lighting.

Table 7 Comparison between dietary groups 12 months after the provision of UVB lights.

Parameter	Dietary group	Mean year 3	Kruskal-Wallis ANOVA statistic	p value
Ionised Calcium	Seed	1.23	0.19	0.6620
	Pellet	1.24		
Total Calcium	Seed	2.22	0.04	0.8428
	Pellet	2.22		
Vitamin D	Seed	139.66	0.37	0.5446
	Pellet	115.44		
Parathyroid hormone	Seed	20.67	0.00	1.0
	Pellet	19.23		

4.1.4 Correlations

Table 8 displays the correlations between plasma calcium parameters investigated during the study. There was no significant correlation between total calcium and albumin in years 1 and 2 using a Pearson correlation test. In the third year a significant correlation was found between total calcium and albumin using a Pearson correlation test. There was no significant correlation found between parathyroid hormone and ionised calcium at any stage during the study using a Pearson correlation test.

Using a Pearson correlation test there was no significant correlation found between parathyroid hormone and 25 hydroxycholecalciferol at any stage of the study.

Table 8 Correlations between calcium parameters investigated during study.

Parameter (x)	Parameter (y)	Year 1		Year 2		Year 3	
		r^2	p	r^2	p	r^2	p
Albumin	Total calcium	0.22	0.1913	0.24	0.1637	0.66	0.0001
25 hydroxycholecalciferol	Ionised calcium	0.05	0.7858	0.25	0.1380	- 0.23	0.2211
Parathyroid hormone	Ionised calcium	- 0.02	0.9016	- 0.02	0.9233	- 0.03	0.4667
Parathyroid hormone	25 hydroxycholecalciferol	- 0.18	0.2860	0.38	0.2000	0.16	0.3300

4.1.5 Progeny testing

The progeny from the grey parrots used in the study were all sold with a pre-purchase examination that included ventral-dorsal and lateral radiographs to rule out evidence of osteodystrophy (figures 26 & 27). Nineteen birds were produced throughout the three years of the study (Table 9)

Table 9 Incidence of radiographic evidence of juvenile osteodystrophy in progeny produced by the study group.

Year of study	Diet Group	Number of weaned progeny	Number of progeny with radiographic evidence of osteodystrophy at 8 weeks
Year 1	Seed	0	0
	Seed	0	0
Year 2	Seed	1	1
	Pellet	6	0
Year 3	Seed	5	0
	Pellet	7	0

The poor reproductive performance did not permit statistical analysis of the results.

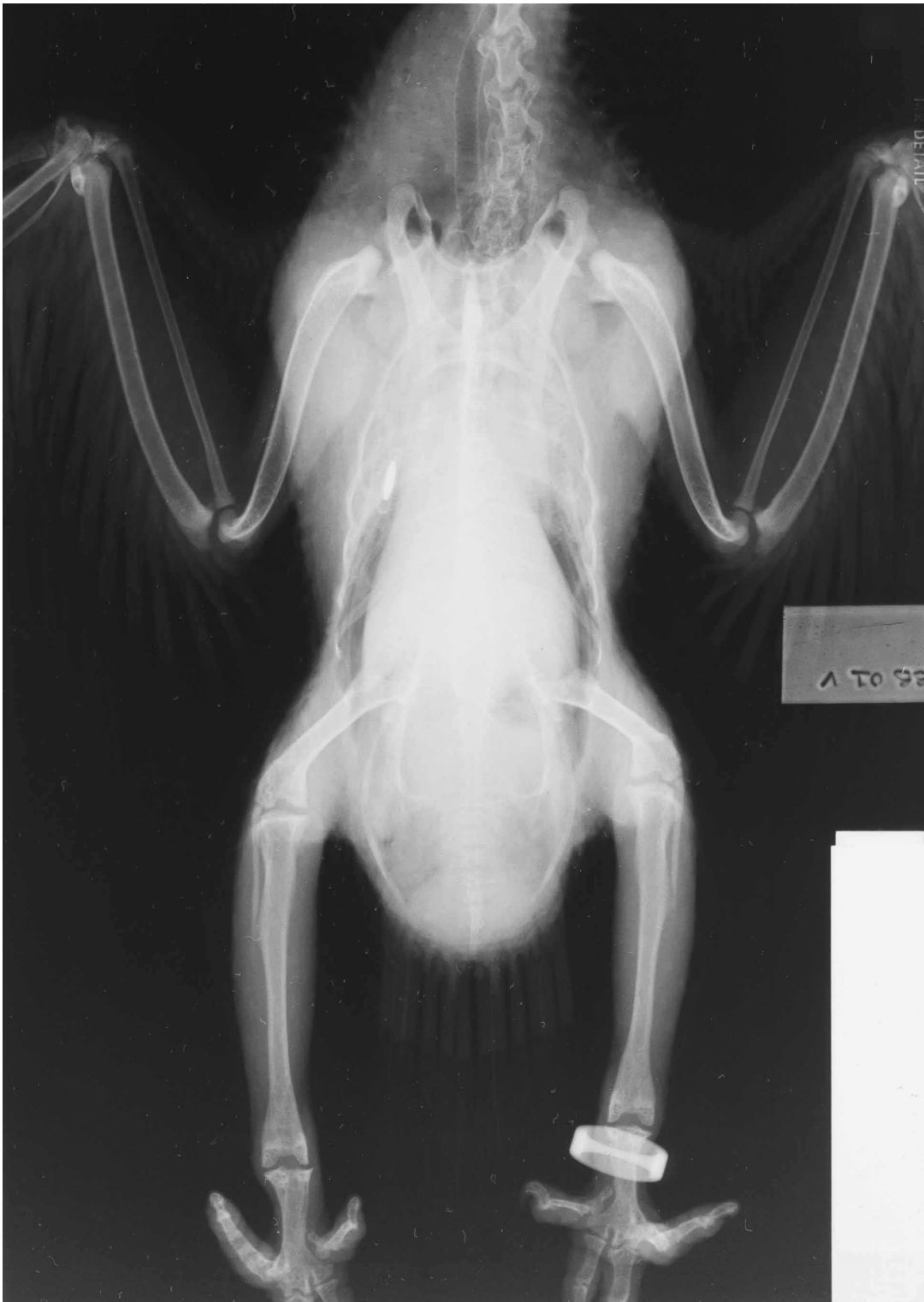

Figure 26. A typical ventral dorsal radiograph from a pellet fed grey parrot demonstrating normal skeletal growth in the species.

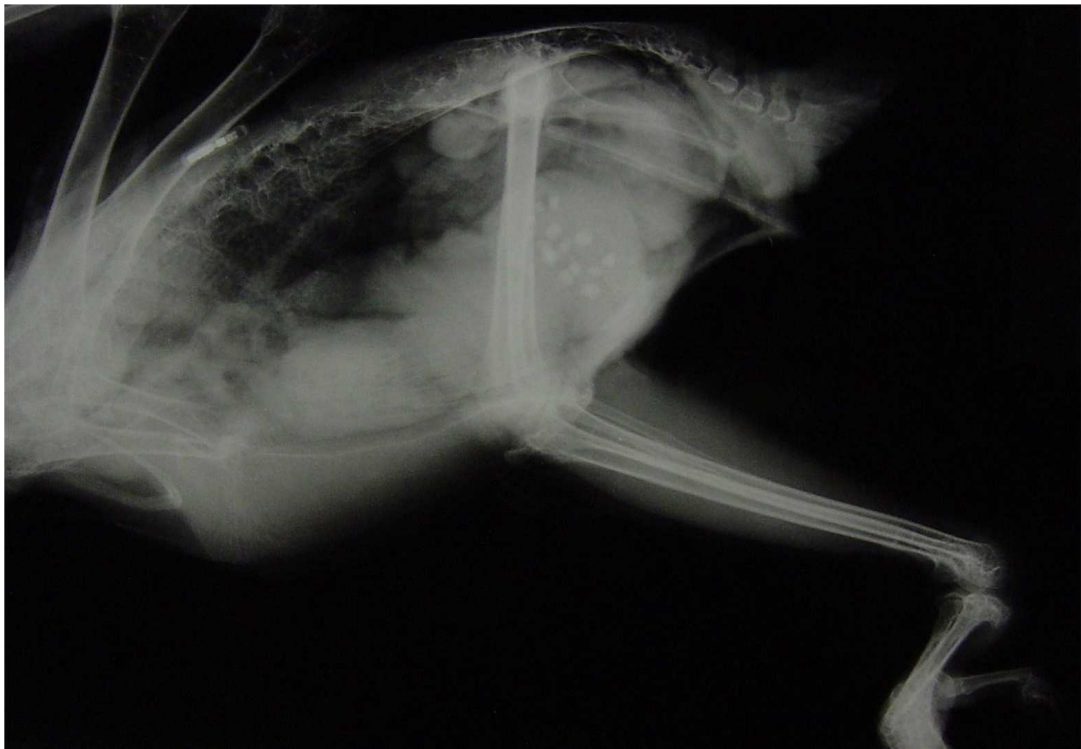

Figure 27. A typical lateral radiograph from a pellet fed grey parrot demonstrating normal skeletal growth in the species.

4.2 Effect of gender on calcium metabolism

Each dietary group had 10 birds of each sex. The data were analysed with respect to gender to identify if there were significant differences in the calcium parameters between the sexes (Tables 10-17). A Mann-Whitney U test did not identify any significant differences between ionised calcium, total calcium, 25 hydroxycholecalciferol or parathyroid hormone with respect to gender throughout the three years of the study in the seed fed group.

A Mann-Whitney U test did not identify any significant differences between ionised calcium, total calcium, 25 hydroxycholecalciferol or parathyroid hormone with respect to gender throughout the three years of the study in the pellet fed group.

Table 10 Effect of gender on ionised calcium concentrations in seed group.

Year of Study	Gender	Mean	SD	SE	Median	95% of confidence limits of mean
Year 1	Female	1.09	0.06	0.02	1.09	1.05-1.14
	Male	1.08	0.06	0.02	1.08	1.04- 1.12
Year 2	Female	1.12	0.05	0.02	1.15	1.10-1.15
	Male	1.11	0.06	0.02	1.09	1.06-1.15
Year 3	Female	1.23	0.07	0.02	1.26	1.17-1.28
	Male	1.23	0.02	0.01	1.23	1.21-1.24

Table 11 Effect of gender on total calcium concentrations in seed group.

Year of Study	Gender	Mean	SD	SE	Median	95% of confidence limits of mean
Year 1	Female	2.01	0.21	0.07	2.11	1.86-2.17
	Male	1.97	0.16	0.06	2.04	1.83-2.10
Year 2	Female	2.00	0.08	0.03	1.97	1.93-2.10
	Male	1.99	0.16	0.05	2.00	1.88-2.11
Year 3	Female	2.22	0.07	0.04	2.23	2.14-2.31
	Male	2.22	0.02	0.02	2.22	2.17-2.27

Table 12 Effect of gender on 25 hydroxycholecalciferol concentrations in seed group.

Year of Study	Gender	Mean	SD	SE	Median	95% of confidence limits of mean
Year 1	Female	30.21	16.80	5.94	23.50	16.16-44.26
	Male	31.92	19.03	6.34	24.30	17.29-46.60
Year 2	Female	79.41	108.34	36.10	33.60	3.89-162-71
	Male	66.85	77.30	27.33	35.85	2.22-131.48
Year 3	Female	175.62	80.02	30.24	148.30	101.62-249.63
	Male	107.78	46.36	15.45	116.8	72.14-143.43

Table 13 Effect of gender on parathyroid hormone concentrations in seed group.

Year of Study	Gender	Mean	SD	SE	Median	95% of confidence limits of mean
Year 1	Female	80.21	62.53	19.77	74.35	35.47-124.94
	Male	46.23	51.56	16.30	46.23	9.35-83.11
Year 2	Female	24.61	17.97	5.99	19.90	10.79-38.43
	Male	26.88	25.22	7.97	16.85	8.83-44.92
Year 3	Female	19.83	13.02	4.34	16.60	9.82-29.85
	Male	21.48	10.87	3.44	16.05	13.71-29.25

Table 14 Effect of gender on ionised calcium concentrations in pellet group.

Year of Study	Gender	Mean	SD	SE	Median	95% of confidence limits of mean
Year 1	Female	1.09	0.04	0.01	1.09	1.06-1.12
	Male	1.06	0.04	0.01	1.07	1.03- 1.09
Year 2	Female	1.19	0.06	0.02	1.19	1.05-1.24
	Male	1.17	0.08	0.03	1.17	1.11-1.23
Year 3	Female	1.25	0.05	0.02	1.25	1.21-1.29
	Male	1.24	0.04	0.01	1.24	1.21-1.27

Table 15 Effect of gender on total calcium concentrations in pellet group.

Year of Study	Gender	Mean	SD	SE	Median	95% of confidence limits of mean
Year 1	Female	1.86	0.16	0.05	1.88	1.75-1.97
	Male	1.94	0.10	0.03	1.95	1.87-2.01
Year 2	Female	2.09	0.15	0.05	2.06	1.96-2.22
	Male	2.07	0.07	0.03	2.04	2.00-2.15
Year 3	Female	2.22	0.09	0.03	2.22	2.16-2.30
	Male	2.20	0.12	0.04	2.22	2.11-2.30

Table 16 Effect of gender on 25 hydroxycholecalciferol concentrations in pellet group.

Year of Study	Gender	Mean	SD	SE	Median	95% of confidence limits of mean
Year 1	Female	13.72	9.25	3.08	11.70	6.60-20.84
	Male	16.41	14.62	4.87	11.30	5.17-27.65
Year 2	Female	117.80	95.16	30.09	117.60	49.25-185.76
	Male	134.36	123.09	38.93	96.35	46.3-222.41
Year 3	Female	115.21	14.92	4.97	111.10	103.75-126.67
	Male	121.00	17.90	6.69	124.00	104.62-137.37

Table 17 Effect of gender on parathyroid hormone concentrations in pellet group.

Year of Study	Gender	Mean	SD	SE	Median	95% of confidence limits of mean
Year 1	Female	58.13	54.09	17.10	34.15	19.43-96.82
	Male	43.65	50.41	15.94	22.45	13.50-126.03
Year 2	Female	23.14	17.49	5.53	17.90	12.60-24.30
	Male	21.53	13.65	4.31	19.95	11.80-23.90
Year 3	Female	21.40	7.39	2.33	22.00	16.11-26.69
	Male	16.81	6.90	2.30	16.00	12.00-26.00

4.3 Clinical pathology results from hypocalcaemic adult grey parrots.

During the study 19 adult (10 male, 9 female) grey parrots presented with seizures attributable to hypocalcaemia. Table 18 demonstrates the clinical pathology results for all the clinical cases. All 19 birds had a plasma ionised calcium concentration below the reference range but demonstrated normal inorganic phosphate and magnesium concentrations. In comparison with the laboratory's reference range five of the birds had normal total calcium concentrations despite the low ionised calcium levels. The concentration of serum 25 hydroxycholecalciferol was below 50nmol/l in all 19 birds. Although no reference range is published for parathyroid hormone in grey parrots poultry would normally be expected to have very low levels of circulating hormone compared with the concentrations detected in the 5 clinical cases measured in this study.

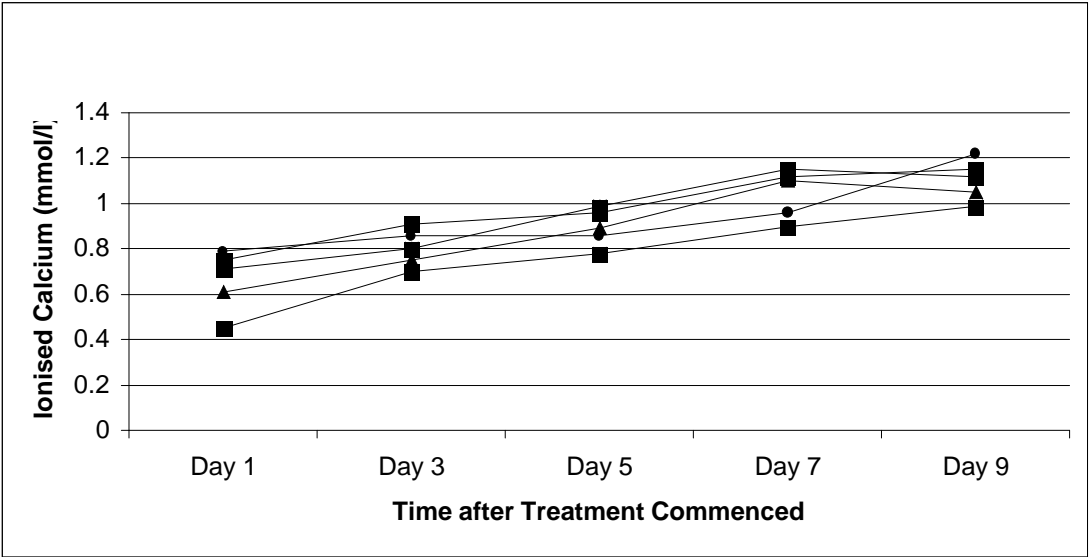
All the birds were successfully treated with no recurrence of hypocalcaemia using a combination calcium and vitamin D supplementation in addition to the provision of UVB light. The response of the plasma ionised calcium concentration to treatment was monitored in 5 birds until the normal range was achieved (Table 19).

Table 18 Clinical pathology results of adult grey parrots with clinical signs of hypocalcaemia.

Parameter	Reference range	n	mean	SD	Median	95% confidence limits of mean
Ionised calcium (mmol/l)	0.96-1.22	19	0.69	0.10	0.71	0.64-0.74
Total calcium (mmol/l)	2.00-3.00	19	1.76	0.54	1.72	1.48-1.99
Inorganic phosphate (mmol/l)		19	1.29	0.25	1.27	1.14-1.41
25 hydroxycholecalciferol (nmol/l)	7.20-380.00	19	10.31	5.33	10.40	7.74-12.88
Parathyroid hormone (pg/ml)	<7.00 *	5	243.62	81.18	220.00	142.82-344.42
1,25 dihydroxycholecalciferol (nmol/l)	No reference range published	10	6.78	3.26	6.45	4.45-9.12
Magnesium		19	0.92	0.13	0.90	0.84-0.94

* Reference range is for poultry as no published data for psittacine birds.

Table 19 Response of plasma ionised calcium concentrations following treatment for hypocalcaemia.



4.4 Wild grey parrot samples

A group of 20 wild grey parrots were blood sampled for ionised calcium and 25 hydroxycholecalciferol concentrations during routine testing for circovirus (Table 20). There was a delay between sample collection and analysis of 72 hours. One sample was rejected from analysis due to haemolysis.

Shapiro-Wilk W tests demonstrated that the data was not normally distributed for the ionised calcium or 25 hydroxycholecalciferol concentrations for the wild grey samples.

A Mann-Whitney U test revealed that ionised calcium concentrations in the wild birds were significantly lower than the captive greys at any stage in the study irrespective of dietary group.

25 hydroxycholecalciferol concentrations were not found to be significantly different between the seed fed group and the wild greys for the first two years of the study using a Mann-Whitney U test. In the third year of the study the 25 hydroxycholecalciferol concentrations were significantly greater than the wild group.

25 hydroxycholecalciferol concentrations were not found to be significantly different from the pellet group and wild birds in the first year of the study but they were significantly greater in the pellet fed group in the second and third year using a Mann-Whitney test.

Table 20 Calcium metabolism concentrations in wild grey parrots.

Parameter	Number in group	Mean	SD	SE	Median	95% CL of mean
Ionised Calcium (mmol/l)	19	1.02	0.05	0.01	1.01	0.99-1.04
25 hydroxycholecalciferol (nmol/l)	19	33.68	53.27	12.22	20.00	8.00-59.36

4.5 SOUTH AMERICAN BIRDS

Twenty eight blood samples supplied to the author from a collection of mixed *Pionus* spp. parrots were analysed in August 2003 for ionised calcium and 25 hydroxycholecalciferol. Ten of the birds had been kept outdoors exposed to natural sunlight. Eighteen birds had been indoors with no exposure to ultraviolet radiation. The birds had been fed an identical pulse based diet supplemented with a vitamin and mineral supplement (Avimix TM, Vetark products, Winchester, UK). Shapiro-Wilk W tests demonstrated that the data was not normally distributed for the ionised calcium or 25 hydroxycholecalciferol concentrations at any stage of the study. A Mann-Whitney U test revealed no significant difference between either the plasma ionised calcium or 25 hydroxycholecalciferol concentrations between the two groups despite the different exposure to UVB light.

A further set of blood samples was analysed from 27 mixed pionus spp. birds, kept in North Yorkshire and exposed to natural sunlight, for both ionised calcium and 25 hydroxycholecalciferol in March 2004 and August. The National Radiation Protection Board reported that the UVI was higher in August than March in the North Yorkshire area. A Wilcoxon sign rank test no significant difference was found between the serum 25 hydroxycholecalciferol and ionised calcium concentrations between the March and August samples despite the increased UVI received by the birds in August.

Table 21 Effect of different UVB conditions on calcium parameters in South American parrots (*Pionus spp.*).

Group	n	Mean ionised calcium +/- SD (Median)	Mean 25 hydroxycholecalciferol +/- SD (Median)
UV-B	10	1.143 +/- 0.001 (1.19)	168.13 +/- 109.02 (145.00)
No UV-B	18	1.103 +/- 0.088 (1.12)	250.01 +/- 126.65 (180.60)

Table 22 Effect of seasonality on calcium parameters in South American parrots (*Pionus spp.*)

Time of sampling	n	Mean ionised calcium +/- SD (Median)	Mean 25 hydroxycholecalciferol +/- SD (Median)
March	27	1.16 +/- 0.06 (1.15)	220.78 +/- 96.58 (178.50)
August	27	1.13 +/- 0.07 (1.14)	160.92 +/- 90.58 (18.58)

4.6 Pathological findings in clinical cases of juvenile osteodystrophy in grey parrots.

12 young grey parrots were presented to the author with clinical and radiographic evidence of juvenile osteodystrophy affecting mobility during the study (figures 28 & 29). Nine birds were treated surgically for the condition with a return to normal mobility. 3 birds were euthanased on humane grounds due to severity of the condition. The histological findings were consistent in all three grey parrots (figures 30,31,32 & 33).

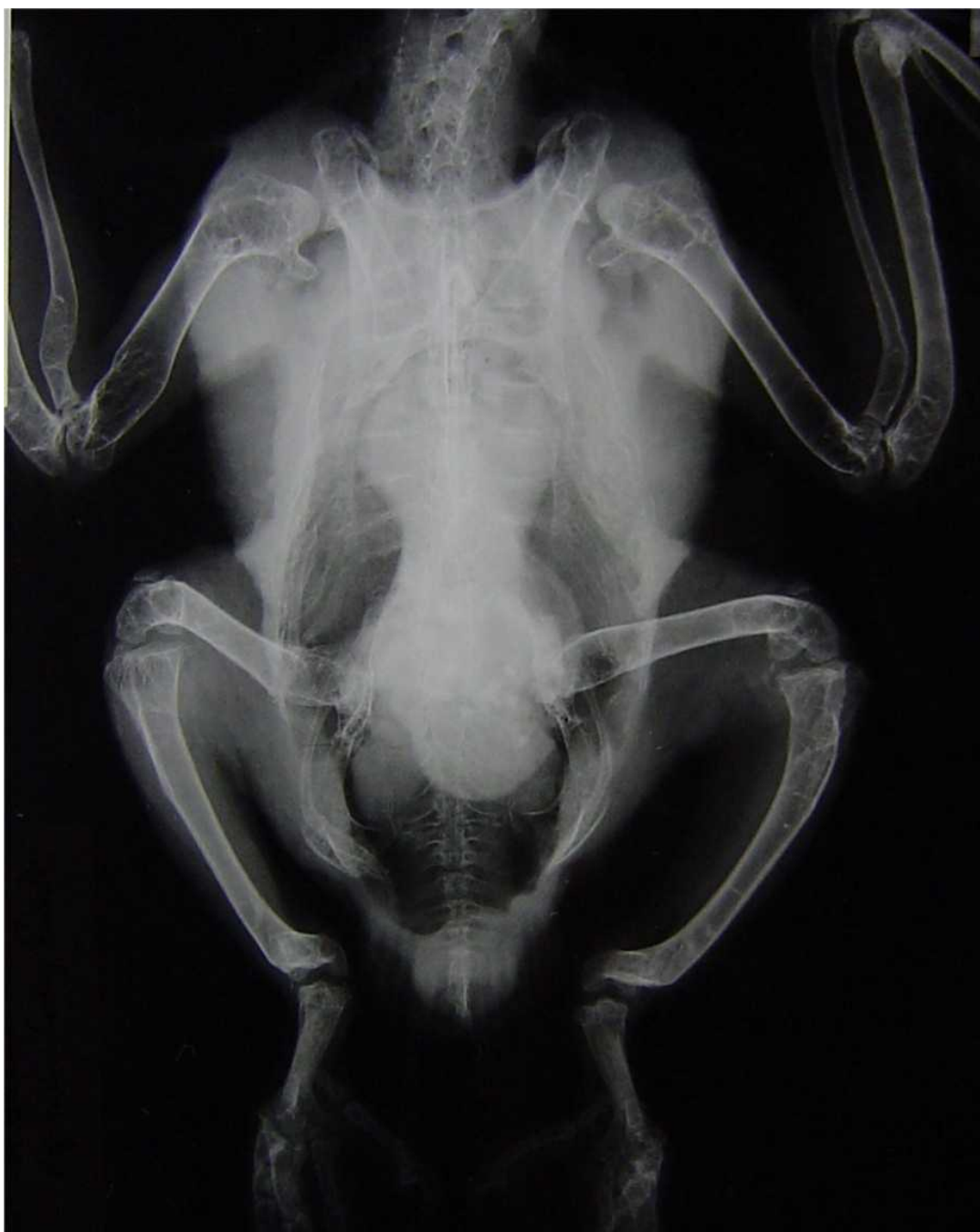

Figure 28. A typical ventral-dorsal radiograph from a grey parrot with juvenile osteodystrophy demonstrating abnormal skeletal growth. Numerous bilateral structural changes are visible in the humerus, radius, ulna, femur, tibiotarsus, synsacrum and spine.

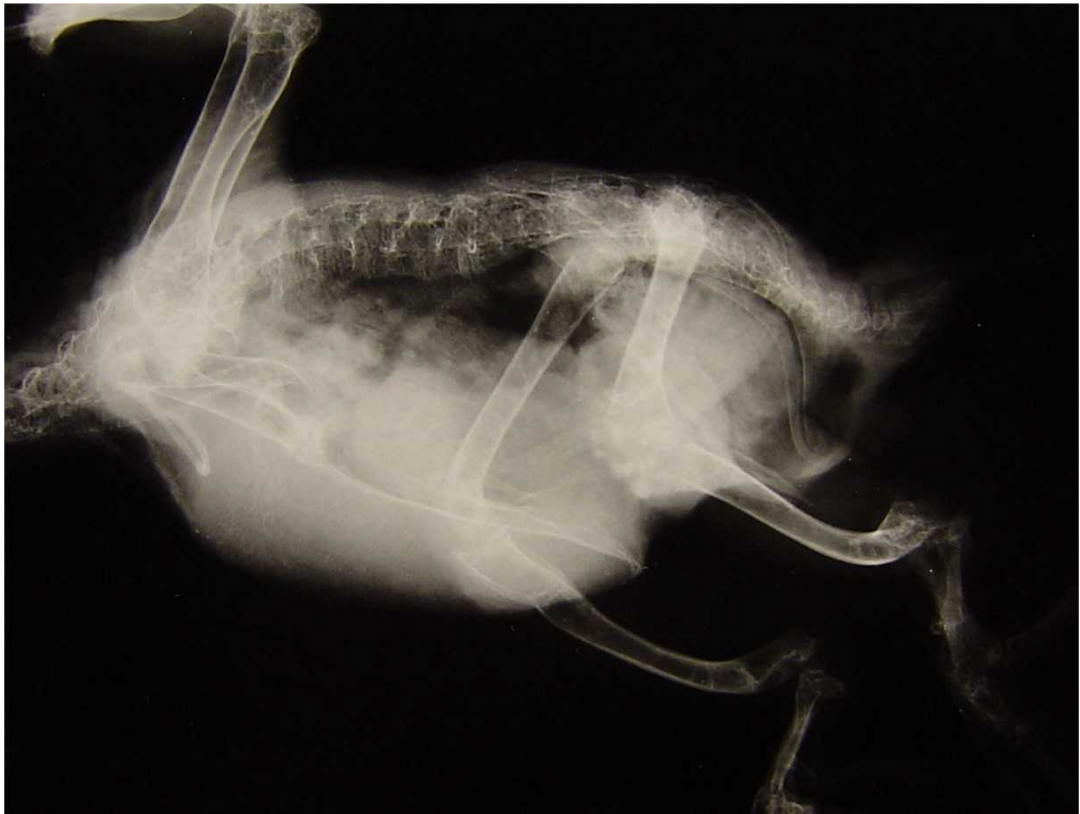

Figure 29. A typical lateral radiograph from a grey parrot with juvenile osteodystrophy demonstrating abnormal skeletal growth. Numerous bilateral structural changes are visible in the humerus, radius, ulna, femur, tibiotarsus, synsacrum and spine.

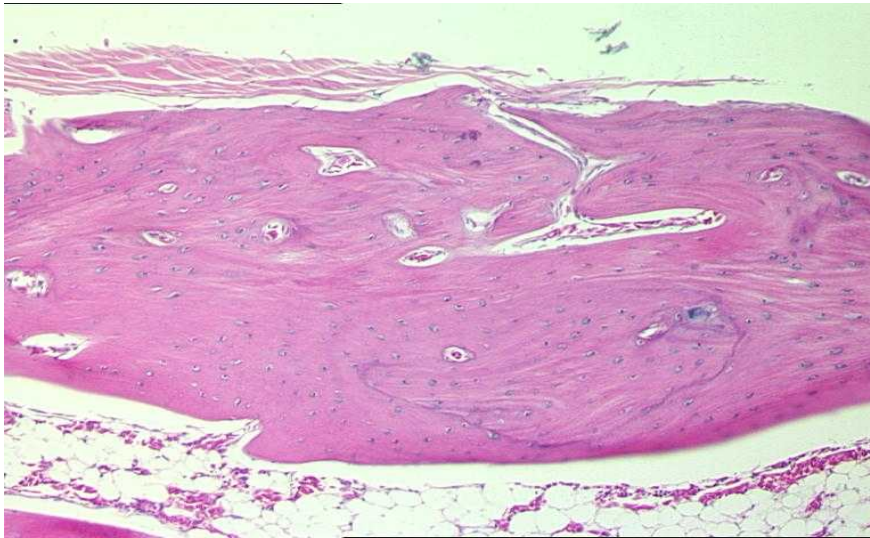


Figure 30. Section of cortical bone from a skeletally normal 12 week old grey parrot. (Haematoxylin and eosin 200X).

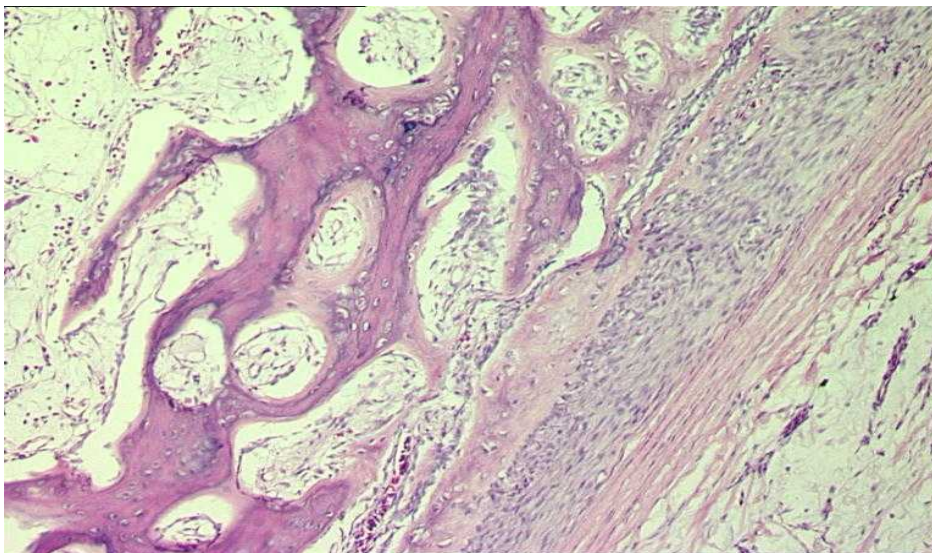


Figure 31. Section of cortical bone from a grey parrot with juvenile osteodystrophy. There is a loss of normal osteoid and replacement with fibrous tissue especially in the periosteal region compared with figure 30. (Haematoxylin and eosin, 200X).

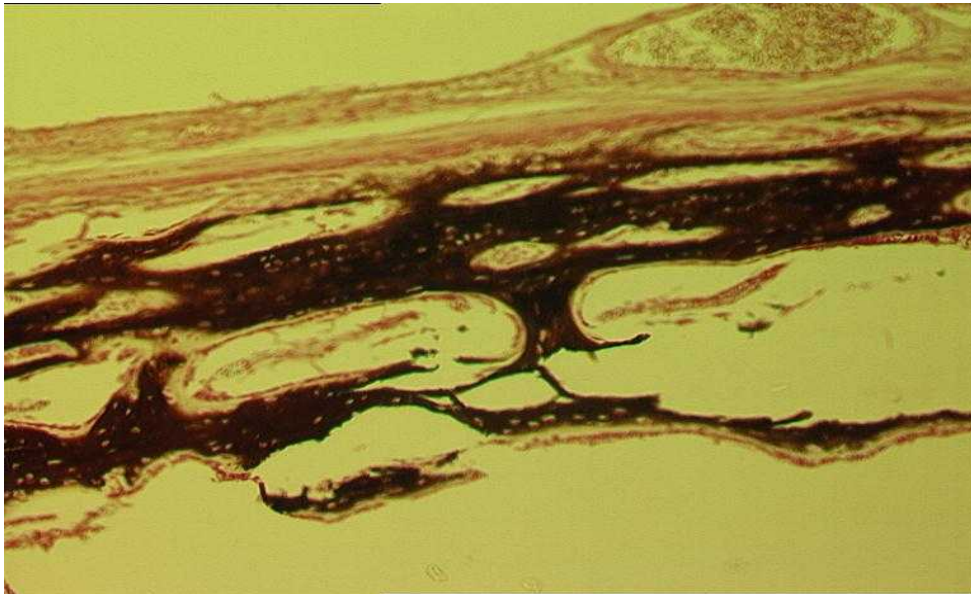


Figure 32. Section of cortical bone stained specifically for minerals from a grey parrot with juvenile osteodystrophy. The section demonstrates the reduction in mineralisation of the bone. (Von Kossa, 200X).

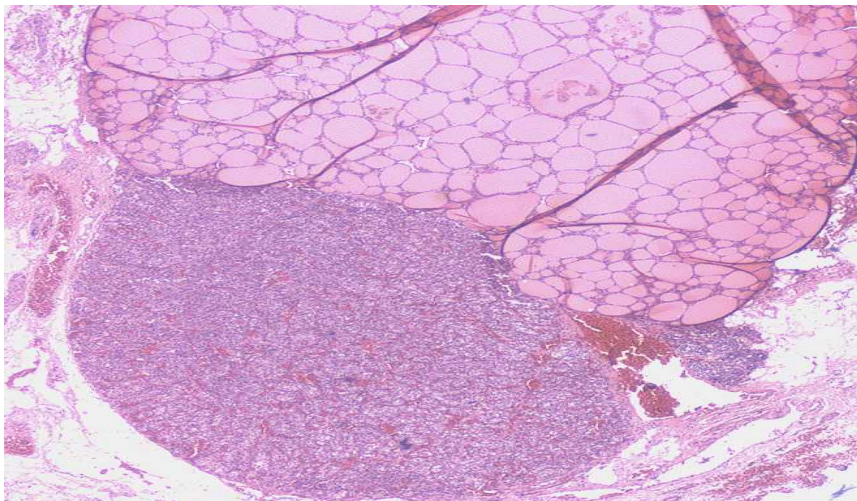


Figure 33. Parathyroid gland from a 6 week old grey parrot with juvenile osteodystrophy. The gland is obviously enlarged and vacuolated consistent with hyperparathyroidism. The adjacent thyroid gland is shown for comparison. (Haematoxylin and eosin, 20X).

4.6.1 Histomorphometrical statistical analysis

Despite the subjective nature of histopathology and the small group sizes involved an attempt was made to quantify and analyse the differences between the osteodystrophic and control birds by measuring the identical parameters in the bone in both groups (Tables 23 & 24). The epiphyseal zone length measurements were not normally distributed according to the Kolmogorov-Smirnov test. Using the Mann Whitney U test the proliferative and hypertrophic zones of both the tibiotarsus and humerus were significantly greater in osteodystrophic birds than control birds. Trabecular area was, however, significantly greater among the control birds compared with the osteodystrophic parrots. The spongiosa length was not significantly different between affected birds and controls.

The epiphyseal width measurements were normally distributed according to the Kolmogorov-Smirnov test. There was no significant difference between the widths of the control and diseased birds using an independent samples t test.

Trabeculae numbers, osteoclast numbers and trabecular area measurements were not normally distributed for either group. There was no significant difference between osteoclast or trabecular numbers between the two groups according to the Mann Whitney U test.

4.6.2 Peripheral Quantitative Computed Tomography (pQCT) of grey parrots

Table 25 demonstrates the pQCT results. Cortical bone mineral density was significantly higher among the control birds at 33% tibiotarsal and humeral bone length by the Mann Whitney U test. Trabecular bone density was significantly greater in the control group for the humerus at the 33% length. At the proximal position, cortical and trabecular bone mineral densities showed no significant difference between the two groups in the humerus by the Mann Whitney U test. There was no significant difference in the cortical bone mineral density in the tibiotarsus by the Mann Whitney U test. There was a failure in the pQCT technique measuring the trabecular bone mineral density of both the proximal and 33% length tibiotarsus in the control group.

Table 23 Histomorphometrical analysis of tibiotarsus in juvenile grey parrots.

Parameter	Mean (n=3) +/- SD (Median Control	Mean (n=3) +/- SD (Median) Diseased
Osteoclast count	2.78 +/-1.65 (2.00)	4.89 +/- 1.58 (4.33)
Mean trabeculae count	5.33+/-1.21 (5.00)	5.55+/-0.38 (5.33)
Mean trabecular area (mm ²)	14697.27+/-3006.53 (15180.92)	9896.54+/- 757.69 (9933.47)
Diaphysial width	22.61+/- 3.66 (23.65)	28.04+/-3.64 (27.64)
Proliferative zone length (mm)	0.67+/- 0.13 (0.68)	2.14+/- 0.15 (2.21)
Hypertrophic zone length (mm)	1.21+/- 0.29 (1.20)	3.35+/- 0.91 (3.42)
Spongiosa length (mm)	4.48+/- 2.09 (5.02)	5.15+/-1.05 (5.74)

Table 24 Histomorphometrical analysis of humerus in juvenile grey parrots.

Parameter	Mean (n=3) Control +/- SD (median)	Mean (n=3) Diseased +/- SD (median)
Osteoclast count	3.00+/- 1.76 (2.33)	4.45+/- 0.39 (4.67)
Mean trabeculae count	6.77+/- 2.22 (5.67)	5.00+/- 1.46 (5.67)
Mean trabecular area (mm ²)	9641.09+/- 691.47 (9940.00)	5538.30+/- 2031.18 (5997.00)
Diaphysial width	29.43+/- 1.10 (29.43)	33.08+/- 3.00 (33.65)
Proliferative zone length (mm)	0.75+/- 0.09 (0.77)	1.34+/- 0.24 (1.43)
Hypertrophic zone length (mm)	1.43+/- 0.50 (1.35)	4.10+/- 0.81 (4.19)
Spongiosa length (mm)	5.12+/- 1.44 (5.91)	4.31+/- 1.75 (4.15)

Table 25 pQCT analysis of bone mineral density in tibia/tarsus and humerus.

Area of interest	Bone analysed	Mean (n) +/- SD (median) control group (mg/cm ³)	Mean (n) +/- SD (median) diseased group (mg/cm ³)
Proximal trabecular bone mineral density	Humerus	209.87 (7) +/- 65.11 (187.20)	180.70 (3) +/- 2.99 (180.53)
	Tibia/tarsus	pQCT failed	105.97 (3)+/-94.43 (136.69)
Proximal cortical bone mineral density	Humerus	341.80 (7)+/- 59.10 (359.90)	194.34 (3) +/- 168.46 (285.65)
	Tibia/tarsus	377.21 (7) +/- 16.60 (376.43)	192.32 (3) +/- 167.52 (270.54)
Trabecular bone mineral density at 33% bone length	Humerus	171.24 (7) +/- 64.87 (166.80)	146.36 (3) +/- 27.68 (135.44)
	Tibia/tarsus	pQCT failed	87.83 (7) +/- 42.34 (68.54)
Cortical bone mineral density at 33% bone length	Humerus	912.88 (7) +/-103.03 (936.80)	310.86 (3) +/- 14.57 (310.65)
	Tibia/tarsus	913.32 (7) +/- 113.53 (866.56)	326.31 (3) +/- 47.10 (320.75)

4.7 Economic cost of different husbandry protocols

The table indicates the approximate cost of feeding the various diets used in the study per bird per day. The cost of feeding pellet diet was approximately 6 times the cost of seed. The cost of providing ultraviolet light involved both the cost of the UVB tubes and electricity utilised.

Table 26 Approximate costs of different husbandry protocols.

Parameter	Approximate Cost Per Bird Per Day
Tidy Mix TM Diet	£0.09
Harrisons High Potency Course Pellets	£0.40
Artificial UVB (including electricity @ £0.05/Kwh)	£0.11
Pulse diet supplemented with Avimix	£0.12

CHAPTER 5

Discussion

5.1 Effects of husbandry changes on calcium metabolism in grey parrots

5.1.1 Year 1 all seed fed

Previous work by the author produced normal ranges for ionised calcium (0.96-1.22mmol/l) and vitamin D (7.2-380nmol/l) in the seed fed captive grey parrot (Stanford M.D. 2003a, Stanford M.D. 2003b). At the end of the first year of the study prior to distribution into the dietary groups all the birds were normocalcaemic with respect to ionised calcium (mean 1.08mmol/l). Some birds had low total calcium concentrations (normal range 2.00-3.0mmol/l), which could be explained by concurrent low serum albumin concentrations caused by low protein levels in the seed, thereby reducing the protein bound calcium fraction. This was not thought to be of any pathological significance. All 40 birds had normal serum 25 hydroxycholecalciferol concentrations according to the reference range published for grey parrots. The mean serum 25 hydroxycholecalciferol concentration for the 40 birds was found to be 34.37nmol/l. In the laying hen, 25 hydroxycholecalciferol does not normally fall below 26nmol/l, and is usually above 50nmol/l (Dacke C.G. 2000). Sixteen of the 40 seed fed greys had serum 25 hydroxycholecalciferol concentrations below 26nmol/l. This could be explained by a lack of ultraviolet radiation and the low vitamin D₃ content of the seed diet. The mean parathyroid hormone concentration for the 40 birds was 57.06pg/ml. No normal parathyroid hormone range for poultry has been published. It has been suggested that poultry have very low circulating levels of PTH ranging from 0-7 pg/ml (Singh R. & others 1986). The results in the grey parrots were significantly higher than this but it is probably more advisable to compare parathyroid concentrations between individual

grey parrots rather than with poultry due to the lack of reference data available for either species.

5.1.2 Year 2 The effect of diet on calcium parameters

At the end of the second year serum samples from the seed fed group revealed no significant changes in ionised calcium, total calcium and 25 hydroxycholecalciferol concentrations, whereas significant changes were seen in these parameters in the pellet group. This can be explained by the presence of increased vitamin D (1650 iu/kg) and calcium (0.09%) in the diet compared with the seed group (0.0 iu/kg and 0.08% respectively). One of the aims of this study was to demonstrate scientifically that mixed seed diets are not suitable for captive parrots, as despite veterinary advice parrot owners are reluctant to change from traditional diets. A survey in the author's practice (n=100) 79% of parrot owners presenting birds to the clinic for examination fed a diet with seed as the main component. Analysis of the seed diet used in the study revealed that not only was there low calcium content but that this was exaggerated by high phosphorus content. This adverse calcium to phosphorus ratio reduces the availability of dietary calcium from the intestines due to the formation of phylate complexes. In addition there was no detectable dietary vitamin D₃ available in the seed so the birds were dependent on endogenous vitamin D₃ synthesis. This was a major concern as the birds were kept indoors without access to natural sunlight. This was discussed with the owner of the birds once the diet analysis was performed at the end of the second year. It was suggested that the birds in the seed control group despite being normocalcaemic should be the subject of dietary improvement on ethical grounds but the owner declined on economic reasons. Following completion of the study all birds were returned to the seed diet. The economic cost of using the pellet diet rather than a seed based diet deters many bird keepers from change. On the basis of this research, the author would recommend studies involving birds should always provide adequate nutrition in the form of a pellet diet or by supplementing cereal based diets adequately with multivitamins. A reduction in phosphorus concentration in the seed diets would generally be prudent. Care should also be taken with the dietary levels of the other fat-soluble vitamins, which compete with vitamin D₃ for the same receptor sites for

absorption from the intestine. Recent work has suggested that vitamin A toxicity is more prevalent than was initially realised and this could lead to secondary vitamin D₃ deficiency due to competition for these receptors. This has been reported in the domestic fowl but it is unlikely to play an important role in the aetiology of hypocalcaemia in grey parrots as most cereal diets are deficient in vitamin A. The diets used in this study had relatively low vitamin A content and would be unlikely to interfere with vitamin D₃ metabolism.

Interpretation of parathyroid hormone concentrations in the present study is difficult. There was a significant decrease in parathyroid hormone concentrations in both the seed and pellet fed groups in year 2 despite no significant changes in the other calcium parameters in the seed group. This may reflect the difficulty in performing parathyroid assays due to the lability of the hormone and complexity of the assay. Another possible explanation is that the birds received more natural ultraviolet light in the second year promoting vitamin D₃ metabolism but the ultraviolet meters present throughout the study did not detect this. It was not possible to validate the parathyroid hormone 1-34 assay due to the large blood volumes required. This meant that the parathyroid hormone data is of limited use in the author's opinion. Future research would be to validate and simplify the PTH 1-34N assay so it could be used commercially in hypocalcaemic birds but this was beyond the scope of this study on both economic and ethical grounds. This author has demonstrated that the traditional PTH 1-84 assay has no relevance as a PTH assay in parrots and this potentially explained why previous studies had problems assaying parathyroid hormone (Stanford M.D. 2002a, Stanford M.D. unpublished data). It appeared to be possible to assay PTH 1-34N in the birds but no linear correlation could be found between ionised calcium concentrations and parathyroid levels.

This study confirms that raising the dietary concentrations of calcium and vitamin D₃ content it is possible to significantly increase serum ionised calcium and 25 hydroxycholecalciferol concentrations in captive grey parrots, as is the case for poultry. This should, in turn reduce the manifestations of hypocalcaemia in grey parrots.

5.1.3 Year 3 The effect of ultraviolet light on calcium parameters

The results at the end of the third year of the study demonstrated the effects of ultraviolet light on calcium parameters in the grey parrot. The use of artificial ultraviolet light significantly increased the plasma ionised calcium and total calcium concentrations in both dietary groups. Plasma vitamin D₃ concentrations were significantly increased in the seed fed group but not the pellet fed group. This suggests that the pellet fed group already had adequate stores of vitamin D₃ from the diet in the form of 25 hydroxycholecalciferol. UVB light does not lead to vitamin D₃ toxicity in the pellet fed group due to the feedback mechanisms in vitamin D₃ metabolism. It would be reasonable to suggest that the 25 hydroxycholecalciferol concentrations seen in healthy birds exposed to UVB light and fed a pellet diet could be used to develop a healthy normal range for the species. This would be clinically useful when investigating parrots suffering suspected hypocalcaemia or hypovitaminosis D₃. Although the use of ultraviolet lighting has been widespread in reptile husbandry it has only recently been suggested as potentially useful in aviculture. The main function of supplementary full spectrum ultraviolet lighting in captive bird husbandry is to enable the birds to see ultraviolet markings in the plumage leading to increased fertility and fecundity (Wilkie S.E. & others 1998). This is thought to be the effect of UVA radiation not UVB. The effect of artificial UVB lighting on vitamin D₃ metabolism in parrots has not been fully considered by the manufacturers. The results suggest that grey parrots in the wild are dependent on ultraviolet light for normal vitamin D₃ metabolism. The majority of captive grey parrots are either kept indoors or live in northern latitudes where they do not receive adequate ultraviolet light compared with those living in equatorial Africa. Endogenous vitamin D₃ synthesis is also known to be a temperature dependent reaction and the majority of captive grey parrots are generally maintained at lower environmental temperatures than their wild counterparts. There was no significant difference in the ambient temperature in the parrot house during the three years of the study but further research might be performed on the effects of temperature on vitamin D₃ metabolism in birds. Failure to provide adequate ultraviolet radiation in captivity may explain why grey parrots are so susceptible to signs of hypocalcaemia. It is proposed by the author that grey parrots should be provided with UVB radiation as part of their husbandry protocol.

Preferably this should come from solar radiation, as there are potential problems with supplying artificial UVB with light both from the performance of the lamps and the practicalities of keeping the bulbs close to the birds. Poultry have been shown to have no vitamin D₃ requirement (Edwards H.M. Jr, 2003) if they are supplied adequate ultraviolet light and this may be the case with grey parrots too. In the present study 2.4% UVB bulbs were used, whereas most captive reptiles vivaria have 5% UVB bulbs. A potential problem with this study was the sensitivity of the UVB meter. The major cause of damage to antiquities in museums is exposure to UV radiation and the monitor used in the study was one designed to detect the amount of UV falling on museum exhibits. Although it could detect UV radiation in the 400-285nm wavelengths a more precise meter detecting specifically in the 315-285nm wavelengths, responsible for vitamin D₃ synthesis, would ensure that the birds were exposed to sufficient UV radiation. Unfortunately although such meters are available for industrial use they are prohibitively expensive. The results from the meter did suggest a steady and constant increase in the radiation received by all the birds in the study compared with the previous years. The significant increase in plasma ionised calcium concentrations combined with no significant fall in parathyroid hormone levels, may be explained by the fact that all the birds were normocalcaemic throughout the study. Parathyroid hormone concentrations should only rise significantly in birds struggling to maintain normal ionised calcium concentrations. This is confirmed by the high parathyroid hormone concentrations obtained from the 5 clinically hypocalcaemic birds. This part of the study has demonstrated the usefulness of ultraviolet light for improving poor but inexpensive cereal based diets with respect to vitamin D₃ metabolism. There was no significant difference between the two dietary groups in serum ionised calcium, total calcium and 25 hydroxycholecalciferol concentrations after the provision of UVB radiation. The author now routinely recommends the provision of artificial UVB light for captive grey parrots in addition to a formulated pellet diet.

5.1.4 Breeding performance and progeny testing

The breeding performance of both dietary groups of birds in the main study improved significantly following the introduction of ultraviolet lighting during the third year. It is not

certain whether this was due to the improvement in calcium metabolism or improved mating behaviour in the birds due to the presence of UVA radiation. The appearance of the birds' plumage between the two groups was very different by the end of the second year of the study. The seed fed group had brittle plumage with numerous fret marks and feather breaks compared with the pellet fed group, who had brighter plumage, which was in much better condition. After the provision of the UVB radiation it was impossible to tell the two groups apart from the point of appearance. Improved preening behaviour under the artificial lighting may have been partly responsible for this difference rather than a solely nutritional action. It would be useful to research this finding in a more quantitative manner as it may have significant effects on the breeding performance of birds. The seed fed birds produced one chick with radiographic evidence of osteodystrophy but the numbers of progeny produced over the 3 year study period was not sufficient to allow statistical analysis.

5.2 Wild birds

The wild birds were found to have ionised calcium concentrations significantly lower than any of the results in the healthy captive birds. These birds had been blood tested at point of capture so a low ionised calcium result might be explained by handling stress affecting acid base balance. There was also a delay between sampling and analyses so direct comparisons between the captive and wild birds should be made with caution. Concentrations of vitamin D₃ did not significantly vary between the wild birds and the captive birds in the early stages of the study but by the third year the captive group had concentrations significantly higher than their wild counterparts irrespective of dietary group. This highlights the need to be careful when providing dietary vitamin D₃ in the diet as vitamin D₃ toxicity could be induced easily.

Concentrations of 25 hydroxycholecalciferol in grey parrots suffering from hypocalcaemia were significantly lower than those in the wild birds, the pellet fed and seed fed birds. This confirms the usefulness of this vitamin D₃ metabolite as an indicator of the vitamin D status of an individual grey parrot. 25 hydroxycholecalciferol was measured in this study for economic reasons and because it is the best assessment of the vitamin D₃ status of an

individual. In the future it would be useful to assay 1, 25 dihydroxycholecalciferol in healthy grey parrots to further evaluate vitamin D₃ metabolism in these birds. Unfortunately at the present time this can only be achieved using radio immune assay, which is prohibitively expensive. Towards the end of the study more economic assays became available and these were used on the clinical cases in order to assess the function of 1,25 dihydroxycholecalciferol. The results obtained in the hypocalcaemic grey parrots were below than normal ranges quoted for poultry.

5.3 Captive South American birds

Once the effects of ultraviolet radiation on calcium metabolism in the grey parrots had been discovered it was decided to investigate a group of 28 healthy pionus parrots kept under varying light conditions fed on mixed pulses and seed. The results of the initial study suggested that there was no difference in plasma ionised calcium and 25 hydroxycholecalciferol concentrations between groups of South American birds kept indoors with no exposure to natural ultraviolet light and those kept outdoors. In a follow up study in 2004 on the same birds it was demonstrated that there was no difference in plasma ionised calcium and 25 hydroxycholecalciferol concentrations between samples taken in March and August in the same individuals despite exposure to naturally increasing ultraviolet light levels. These results suggest that this South American family is not as dependent on ultraviolet radiation for vitamin D₃ synthesis as grey parrots. Unfortunately this part of the study involved small groups of birds and was without the tight dietary controls seen in the main study. Better controlled studies, involving larger numbers of birds, could be performed on South American species, as this work tends to suggest that different psittacine species have different husbandry requirements, possibly explaining why grey parrots are more susceptible to calcium metabolism disturbances. In anthropology it has been suggested that variance in pygmy size and skin pigmentation between tribes living in African rain forest and South American rain forest is due to different evolutionary paths in a response to different ultraviolet light levels received on the forest floor (Hiernaux J. & others 1975). The South American rain forest has a denser tree canopy than the majority of African rain forests and this could explain why African birds appear more dependent than

South American birds on ultraviolet light for adequate vitamin D₃ metabolism. New World monkeys have similar problems to grey parrots with their vitamin D₃ metabolism. The New World species have a higher requirement for UVB radiation than Old World Monkeys (Fiennes R.N. 1974, Miller R.N. 1971). It has been suggested that the New World Monkeys are less efficient in converting provitamin D₃ than other species. An alternative theory is that vitamin D₃ does not bind as efficiently in New World monkeys to carrier proteins. A further theory suggests that this is a case of vitamin D₃ resistance due to failure of the vitamin D₃ receptors. As it becomes feasible to measure vitamin D₃ receptors in birds further research could be carried out in the grey parrots to investigate whether they have an inherent vitamin D₃ resistance. Future research could also determine whether calcium metabolism in grey parrots differs from that in psittacine species. In particular, the effect of ultraviolet light on vitamin D₃ metabolism in other parrot species might be researched further. A breed difference has also been reported in vitamin D₃ concentrations in cockatoos. Major Mitchell cockatoos appear to be susceptible to hypocalcaemia if they are kept in areas with cloud cover reducing the ultraviolet light concentrations (Macdonald D., personal communication).

5.4 Correlations

There was no significant correlation between albumin and total calcium until the third year of the study. Correlation between albumin and total calcium in mammals is only relevant in healthy individuals with normal calcium metabolism. It is feasible that although the birds were normocalcaemic in the first two years of the study, it was not until the third year when all birds had adequate vitamin D₃ and ionised calcium, the correlation between total calcium and albumin became significant. Corrective formulae to adjust total calcium for varying protein concentrations cannot be used reliably in birds in the author's opinion.

There was no significant correlation between either vitamin D₃ or parathyroid hormone and ionised calcium at any stage during the study. This could be explained by the fact the birds were all essentially healthy so only very narrow range of ionised calcium concentrations was assessed. An investigation involving birds with low ionised calcium concentrations might reveal a relationship between parathyroid hormone or vitamin D₃ concentrations and

ionised calcium. Increasing the group sizes might also produce significant correlations. Simple correlations may not occur because multiple factors influence parathyroid hormone synthesis and secretion such as ionised calcium, phosphate and 1,25 dihydroxycholecalciferol. Calcium metabolism is a dynamic system so examining blood samples at a single time point may not give the full picture.

5.5 Gender differences

There were no significant differences between ionised calcium, 25 hydroxycholecalciferol or total calcium concentrations between the sexes at any stage during the study. It might be expected that a mature female bird would have higher circulating calcium concentrations than the male associated with breeding behaviour. It is thought that this was not the case in this study as the samples were all taken out of the breeding season of these birds in the UK.

5.6 Clinical Cases of hypocalcaemia in adult grey parrots.

Results obtained from clinically affected birds confirmed that signs of hypocalcaemia in grey parrots are invariably due to nutritional secondary hyperparathyroidism. All clinical cases presented at the author's practice had low plasma ionised calcium and 25 hydroxycholecalciferol. Low levels of 25 hydroxycholecalciferol suggest poor storage of vitamin D₃ in these birds, predisposing for hypocalcaemia. In addition these birds had low 1,25 dihydroxycholecalciferol concentrations compared with poultry possibly signifying a failure in vitamin metabolism. Measurement of serum ionised calcium during the investigation of disorders of calcium metabolism is considered vital by the author. Five of the 19 clinical cases of hypocalcaemia had a normal serum total calcium concentrations despite both low ionised calcium and 25 hydroxycholecalciferol concentrations. The normal concentrations of total calcium are most probably explained by high albumin concentrations, which increase the pathologically insignificant protein bound fraction of calcium. Traditionally veterinary pathology laboratories routinely assay for total calcium, and not ionised calcium, with the result that hypocalcaemia is probably being under-diagnosed in grey parrots. The data from the dietary study in grey parrots demonstrated no

significant positive correlation between total calcium and albumin in the study except in the final year. Consequently no formula can be used to correct total calcium figures for fluctuations in protein levels in the grey parrot and ionised calcium should be measured directly.

In the 5 clinical cases of hypocalcaemia in grey parrots where it was possible to measure PTH 1-34 the level of parathyroid hormone was significantly elevated over any other parathyroid hormone results found in the study. In the other 14 clinical cases it was not possible to obtain an adequate blood volume for PTH testing due to the severity of the clinical signs. Care should therefore be taken with these results due to the small sample size and difficulty in validating the parathyroid 1-34N assay but they are suggestive of hyperparathyroidism. All the 19 birds made a full recovery although it did take up to a week for serum ionised calcium concentrations to return to normal. The measurement of both 25 hydroxycholecalciferol and 1,25 dihydroxycholecalciferol has been demonstrated by this study to be useful and of significance in the grey parrot. These assays are becoming more affordable and should perhaps form part of any routine investigation of calcium metabolism disorders. Parathyroid hormone assays require further research to validate one that is suitable for grey parrots.

5.7 Grey parrot chicks with juvenile osteodystrophy

5.7.1 Histology Results

Despite the common presentation of osteodystrophy in juvenile grey parrots and hypocalcaemia in adult birds no research has been carried out on the histological changes seen in the parathyroid gland and bone in the birds. The small sample size obtained for this part of the study dictates that the results should be interpreted with extreme caution. This study shows that the histopathological changes in both the parathyroid and bones of grey parrots suffering from hypocalcaemia are consistent with nutritional secondary hyperparathyroidism. Bone densitometry and histological examination of the tissues was found to be particularly useful in the diagnosis of juvenile osteodystrophy, and it was possible to quantify the histopathological findings. There were statistically significant

differences between the bone and growth plate architecture of diseased and control birds. The significantly elongated hypertrophic zone length and wide seams of unmineralised osteoid at the trabecular periphery were consistent with the diagnosis of rickets. Differences in bone width between diseased and control birds were not statistically significant, although they would be expected to be greater in birds with juvenile osteodystrophy. The presence of large numbers of osteoblasts along the trabecular periphery of diseased bone demonstrated attempts at bone repair. Bone responds dynamically to mechanical demands, maintaining strain in the matrix within a narrow and beneficial range. Any decrease in bone mineral density compromises compressional strength and this increases the functional strain experienced by the bone, which acts as a stimulus for osteogenesis. This could explain the slightly higher trabecular density in diseased samples. This difference, however, was not significant and could also be a consequence of the small sample sizes. Trabecular areas were substantially smaller in birds suffering from osteodystrophy. Histological analysis revealed evidence of multifocal dissection osteoclasia. These changes suggest over-stimulation of the bone by PTH. Further evidence suggesting hyperparathyroidism was the marked loss of cortical bone demonstrated in the Von Kossa stained sections. Fibrous tissue proliferation was common in the disease bone sections. Fibrous tissue in bone is usually associated with osteodystrophy, a condition almost exclusively induced by hyperparathyroidism. Osteoclast densities were not significantly different by the Mann Whitney U test. This may be a result of the random selection of areas of interest across the secondary spongiosa, as clusters of osteoclasts were commonly seen microscopically. Parathyroid glands from diseased birds were larger than those from control animals, suggestive of hypertrophy. The chief cells were larger, with a decreased nuclear: cytoplasmic ratio in the osteodystrophic samples a feature indicative of secondary hyperparathyroidism. In conclusion the majority of histomorphological findings support the hypothesis that the bone lesions were characteristic of both rickets and fibrous osteodystrophy caused by secondary hyperparathyroidism. These results appear to confirm that juvenile osteodystrophy is caused by nutritional secondary hyperparathyroidism.

5.7.2 Bone mineral density

The pQCT results were consistent with the histological appearance of cortical bone in both the humerus and tibiotarsus. There was a significant reduction in bone mineralisation of all birds suffering from juvenile osteodystrophy compared with the control birds. This demonstrated that pQCT could be used to distinguish between healthy and diseased bone, although it cannot identify the nature of bone pathology. A decrease in bone mineral density might be associated with rickets due to a failure of bone mineralisation or fibrous osteodystrophy (where dense, lamellar bone is replaced by reactive woven bone). Trabecular bone mineral densities were only significantly different in one part of the humerus (at 33% humeral length). This suggests that cortical bone density is more dramatically compromised in juvenile osteodystrophy. Although the results are promising pQCT is unlikely to be used routinely for the diagnosis of juvenile osteodystrophy in grey parrots as the procedure is expensive and would require sedation in the live parrot. Diagnosis can easily be made on the basis of clinical signs, blood biochemistry and radiography. The pQCT technique does have a potential for assessing the severity of lesions. As it is a non-invasive procedure further work could be carried out on young parrots to determine whether the common practice of hand rearing is associated with the development of osteodystrophy. It could also be useful in the diagnosis of osteodystrophies in other exotic pet species such as dental disease in rabbits and metabolic bone disease in reptiles. The same techniques are being used by the author in a study of metabolic bone disease in collared doves and wood pigeons. The simple radiographic evidence provided by this study suggested that hand rearing techniques do not appear to have a significant role to play in the aetiology of juvenile osteodystrophy in grey parrots. Nutrition of the parent birds, however, did appear to predilect for osteodystrophy in the progeny although the sample size was small. This is perhaps not surprising when young growing parrots are dependent for all their calcium requirements from their parents. In addition the avian embryo acquires most of its calcium from the eggshell and the structure of the egg is dependent on the nutritional status of the parent hen bird. In future, the use of biochemical markers of bone metabolism could be employed to more easily and economically confirm nutritional osteodystrophy in affected birds although at the present time no avian

biochemical markers are available. Such markers should be validated against more direct measures of bone mineral density and bone histomorphometry as applied in the present study.

5.8 CONCLUSIONS

- 1) Nutritional secondary hyperparathyroidism is responsible for hypocalcaemia in adult grey parrots and for juvenile osteodystrophy in grey parrot chicks.
- 2) Increased dietary content of calcium and vitamin D₃ significantly increases plasma ionised calcium and vitamin D₃ concentrations in grey parrots.
- 3) Provision of artificial ultraviolet light in the 315-285nm spectrum significantly increases plasma ionised calcium and vitamin D₃ concentrations in grey parrots independent of the diet.

CHAPTER 6

References

Abawi, F.G. & Sullivan, T.W. (1989) Interactions of vitamins A, D3, E and K in the diet of broiler chicks. *Poultry Science* **68**(11): 1490-8.

Abe, E., Miyaura, C., Tanaka, H., Shina, Y., Kuribayashi, Y., Suda S., Nishii Y., DeLuca H.F. & Suda, T. (1983) 1-alpha-dihydroxycholecalciferol promotes fusion of mouse alveolar macrophages both by direct mechanism and by a spleen cell mediated indirect mechanism. *Proceedings of the National Academy of Sciences, USA* **80**: 5583-5587.

Aburto, A., Edwards, H.M. Jr. & Britton, W.M. (1998) The influence of vitamin A on the utilisation and amelioration of toxicity of cholecalciferol, 25 hydroxycholecalciferol and 1,25 dihydroxycholecalciferol in young broiler chicks. *Poultry Science* **77**(4): 585-93.

Aburto, A. & Britton, W.M. (1998a) Effects of different levels of vitamin A and E on the utilisation of cholecalciferol by broiler chickens. *Poultry Science* **77**(4): 570-7.

Aburto, A. & Britton, W.M. (1998b) Effects and interactions of dietary levels of vitamin A and E and cholecalciferol in broiler chickens. *Poultry Science* **77**(5): 666-73.

Adkins, E., Driggers, T., Ferguson, G. W., Gehrmann, W. H., Gyimesi, Z. S., May, E., Ogle, M. & Owens, T. (2003) Ultraviolet light reptiles and amphibians. *Journal of Herpetological Medicine and Surgery* **13** (4) 27 – 37.

Allen, M.J., Hoffmann, W.E., Richardson, D.C. & Breur, G.J. (1998) Serum markers of bone metabolism in dogs. *American Journal of Veterinary Research* **59**: 250-254.

Allen, M.J. (2003) Biochemical markers of bone metabolism in animals: uses and limitations. *Veterinary Clinical Pathology* **32** (3): 101-113.

Antillon, A., Scott, M.L., Krook, L. & Wasserman, R.H. (1977) Metabolic response of laying hens to different dietary levels of calcium, phosphorus and vitamin D. *Cornell Veterinarian* **167**: 413-444.

Arnold, S.A., Kram, M.A., Hintz, H.F., Evans, H. & Krook, L. (1973) Nutritional secondary hyperparathyroidism in the parakeet. *Cornell Veterinarian* **64**(1): 37-46.

Aslam, S.M., Garlich, J.D. & Qureshi, M.A. (1998) Vitamin D deficiency alters the immune responses of broiler chicks. *Poultry Science* **77**(6): 842-9.

Aucone, B. M., Gehrmann, W. H., Ferguson, G. W., Chen, T. C. & Holick, M. F. (2003) Comparison of two artificial ultraviolet light sources used for Chuckwalla, *Sauromalus obesus*, husbandry. *Journal of Herpetological Medicine and Surgery* **13** (2) 14 – 17.

Austic, R., Baker, D. & Cole, R. (1977) Susceptibility of a dwarf strain of chicken to rickets. *Poultry Science* **56**: 285-291.

Baker, D.H., Biehl, R.R., & Emmert, J.L. (1998) Vitamin D₃ requirement of young chicks receiving diets varying in calcium and available phosphorus. *British Poultry Science* **39**(3): 413-417.

Bannister, D.W. & Candlish, J.K. (1973) The collagenolytic activity of avian medullary bone: effect of laying status and parathyroid extract. *British Poultry Science* **14**:121-125.

Bar, A. & Hurwitz, S. (1980) The 25 hydroxycholecalciferol-1-hydroxylase activity of chicks kidney cells: Direct effect of parathyroid. *FEBS Letters* **113**, 328-330.

Bar, A., Sharvit, M., Noff, D., Edelstein, S. & Hurwitz, S. (1980) Absorption and excretion of cholecalciferol and of 25 hydroxycholecalciferol and metabolites in birds. *Journal of Nutrition* **110**(10): 1930-4.

Bar A., Rosenberg, J., Perlman, R. & Hurwitz, S (1987) Field rickets in turkeys; relationship to vitamin D. *Poultry Science* **66**: 68-72.

Bar, A. & Hurwitz, S. (1987) Vitamin D₃ metabolism and calbindin in aged laying hens. *Journal of Nutrition* **117**(10): 1775-9.

Bar, A., Vax, E. & Striem, S. (1999) Relationship among age, eggshell thickness and vitamin D metabolism and its expression in the laying hen. *Comparative Biochemistry and Physiology* **123**(2): 147-54.

Barber, P.J., Elliot, J. & Torrance, A.G. (1993) Measurement of feline intact parathyroid hormone: Assay validation and sample handling studies. *Journal of Small Animal Practice*. **34**: 614-619.

Barnett, K.C. & Laursen-Jones, A.P. (1976) The effect of continuous ultraviolet irradiation on broiler chickens. *British Poultry Science*. **17** (2) 175-7.

Bartov, I. (1997) Moderate excess of dietary vitamin E does not exacerbate cholecalciferol deficiency in young broiler chicks. *British Poultry Science* **38**(4) 442-4.

Bentley, P.J. (1998) In *Calcium metabolism: Comparative Vertebrate Endocrinology*, pp 269-301. Cambridge University Press, Cambridge, UK.

Berger, B. & Feldman, E.C. (1987) Primary hyperparathyroidism in dogs: 21 cases (1976-1986). *Journal of the American Veterinary Medical Association* **191**: 350-356.

Bernard, J.B. (1995) Spectral irradiance of special fluorescent lamps and their efficiency for promoting vitamin D synthesis in herbivorous reptiles. PhD dissertation, Michigan State University.

Berry, J.L., Farquharson, C., Whitehead, C.C. & Mawer, E.B. (1996) Growth plate chondrocyte vitamin D receptor number and affinity are reduced in avian tibial dyschondroplastic lesion. *Bone* **19**(2): 197-203.

Biovin, G., Mesguich, P., Pike, J.W., Bouillon, R., Meunier, P.J., Haussler, M.R., Buboia, P.M. & Morel, G. (1987) Ultrastructure immunocytochemical localisation of endogenous 1,25 dihydroxycholecalciferol and its receptors in osteoblasts and osteoclasts from neonatal mouse and rat calvaria. *Bone and Mineral*. **3**: 125-136.

Blind, E. & Gagel, R. F. (1999) Assay methods: Parathyroid hormone, parathyroid hormone-related protein and calcitonin. In: *Primer on the Metabolic Bone Disease and Disorders of Bone Metabolism*. (5th edition, M. J. Favus ed.), pp 119-128. Lippencott, Williams and Wilkins, Philadelphia.

Blood, D.C. & Studdert, V.P. (1998) In: *Bailliere's Comprehensive Veterinary Dictionary* (D.C. Blood & Studdert V.P. eds), pp653-654. Bailliere Tindall, London.

Blunt, J.W., Deluca, H.F., & Schnoes, H.K. (1968) 25 hydroxycholecalciferol. A biologically active metabolite of vitamin D₃. *Biochemistry* **7**: 3317-3322.

Boland, R.L.B. (1986) Plants as a source of vitamin D₃ metabolites. *Nutrition Reviews* **44**:1-8.

Boris, A., Hurley, J.F. & Tramal, T. (1977) Relative activities of some metabolites and analogs of cholecalciferol in stimulation of tibia ash weight in chicks otherwise deprived of vitamin D. *Journal of Nutrition* **107**: 194-198.

Bouillon, R., Van Baelen, H., Tan, B.K. & De Moor, P. (1980) The isolation and characterisation of the 25 hydroxycholecalciferol binding protein from chick serum. *Journal of Biological chemistry* **255**(22): 10925-30.

Boyer, T. H. (1996) Metabolic bone disease. In: *Reptile Medicine and surgery*, (D. R. Mader ed.), pp385-392), W. B. Saunders, London.

Brommage, R. & Deluca, H.F. (1985) Evidence that 1,25 dihydroxycholecalciferol is the physiologically active metabolite of vitamin D3. *Endocrinological Reviews* **6**: 491-511.

Brue, R.N. (1994) Nutrition. In: *Avian Medicine: Principals and Applications*, (R.W. Ritchie, G.J.Harrison, L.R. Harrison, eds), pp 63-95. Wingers Publishing, Lake Worth, Florida.

Bruyette, D.S. & Feldman, E.C. (1988) Primary hypoparathyroidism in the dog. Report of 15 cases and review of 13 previously reported cases. *Journal of Veterinary Internal Medicine*. **2**: 7-14.

Burgos-Trinidad, M., Brown, A.J. & DeLuca, H.F. (1990) A rapid assay for 25 hydroxyvitamin D and 1,25 dihydroxycholecalciferol. *Analytical Biochemistry* **190**(1): 102-7.

Bush, B.M. (1991) In: *Interpretation of laboratory results for small animal clinicians*, pp 367-368. Blackwell Scientific, Oxford.

Cain, J.R., Beasom, S.L., Rowland, L.O. & Rowe, R.D. (1982) The effects of varying dietary phosphorus on breeding bobwhites. *Journal of Wildlife Management* 1061-1065.

Candlish, J.K. & Taylor, T.G. (1970) The response time to the parathyroid hormone in the laying fowl. *Journal of Endocrinology* **48**: 143-144.

Carrier, D. & Leon, L.R. (1990) Skeletal growth and function in the Californian Gull (*Larus californicus*). Journal of Zoological Society London **222**: 375-389.

Carrier, D. & Auriemma, J. (1992) A developmental constraint in fledging time in birds. Biological. Journal of the Linnean Society **47**: 61-77.

Castillo, L., Tanaka, Y., Wineland, M.J., Jowsey, J.O. & DeLuca, H.F. (1979) Production of 1,25 dihydroxyvitamin D₃ and formation of medullary bone in the egg laying hen. Endocrinology 104(6): 1598-601.

Cheville, N.F.& Horst, R.L. (1981) Pathology of experimental vitamin D deficiency in chickens and the effects of treatment with vitamin D metabolites. Veterinary Pathology **18**(5): 638-51.

Clark, N.B. (1967) Influence of oestrogens upon serum calcium, phosphate and protein concentrations of fresh water turtles. Biochemical Physiology **20**: 823-834.

Clark, N.B. & Wideman, R.F. (1977) Renal excretion of phosphate and calcium in parathyroidectomised starlings. American Journal of Physiology **233**:138-144.

Clark, N.B., Murphy, M.J. & Lee, S.K. (1989) Ontogeny of vitamin D action on the morphology and calcium transport properties of the chick embryonic yolk. Journal of Developmental Physiology **11**: 243-251.

Classen, H.L. & Riddell, C. (1989) Photoperiodic effects on performance and leg abnormalities in broiler chickens. Poultry Science **68**: 873-879.

Classen, H.L. (1992) Management factors in leg disorders. In: *Bone biology and skeletal disorders in poultry*. Poultry Science Symposium Number Twenty-three (C.C. Whitehead ed), pp 201-203. Carfax Publishing Company, Oxford, UK.

Clunies, M., Emslie, J. & Leeson, S. (1992) Effect of dietary calcium on medullary bone reserves and shell weight in leghorn hens. *Poultry Science* **71**: 1348-1356.

Collar, N.J. (1997) In: *Handbook of the Birds of the World, Vol 4, Sandgrouse to Cuckoos* (del Hoyo J., Elliot A. & Sargatal J. eds), pp 413-414. Lynx Editions, Barcelona, Spain.

Colston, K.W., Evans, I.M., Spelsberg, T.C. & MacIntyre, I. (1977) Feedback regulation of vitamin metabolism by 1,25 dihydroxycholecalciferol. *Biochemistry Journal*. **64** (1): 83-89.

Corradino, R.A. (1985) Effects of verapamil and dexamethasone on the 1,25 dihydroxycholecalciferol mediated calcium absorptive mechanism in the organ cultured embryonic chick duodenum. *Biochemical Pharmacology* **34**: 1971-1974.

Coty, W.A. (1980) A specific high affinity binding protein for 1 α -25 dihydroxycholecalciferol in the chick oviduct shell gland. *Biochemical and Biophysical Research Communications*: 285-292.

Dacke, C.G. (1979) In: *Calcium metabolism in submammalian vertebrates*, pp 77-90. Academic Press, London.

Dacke, C.G. & Kenny, A.D. (1982) Prostaglandins: Are they involved in calcium homeostasis? In: *Aspects of Avian Endocrinology: Practical and theoretical implications* (C.G. Scanes, M.A. Ottinger, A.D.Kenny, J.Balthazart, J.Cronshaw & I. Chester-Jones eds.), pp255-262. Texas Technical University Press, Lubbock.

Dacke, C.G. (2000) In: *Sturkie's Avian Physiology* (5th edition G.C. Whittow ed.), pp 472-485. Academic Press, London.

Deftos, L. J., Roos, B. A. & Oates, E. L. (1999) Calcitonin. In: *Primer on the Metabolic Bone Disease and Disorders of Bone Metabolism*. (5th edition, M. J. Favus ed.), pp 99-104. Lippencott, Williams and Wilkins, Philadelphia.

De Groote, G. (1999) Leg weakness in poultry: Effects of minerals. In: *7th symposium on poultry nutrition*. WPSA June 19-21, 1999; pp 171-186. Lloret de Mar, Girona, Spain.

Deluca, H.F., Nakada, M., Tanaka, Y., Scinski, R. & Phelp, M. (1988) The plasma binding protein for vitamin D is a site of discrimination against vitamin D-2 in the chick. *Archives of Biochemistry and Biophysics* **965**: 16-21.

De Wit, M., Schoemaker, N, J., Kik, M.J.L. & Westerhof, I. (2003) Hypercalcaemia in two Amazon parrots with malignant lymphoma. *Proceedings of the European Association of Avian Veterinarians 7th European meeting, Tenerife, Spain April 22-26. 2003*; 9-11.

Dickson, I.R. & Kodicek, E. (1979) Effect of vitamin D deficiency on bone formation in the chick. *Biochemical Journal* **182**(2): 429-35.

Dokoh, S., Donaldson, C.A., Marion, S.L., Pike, J.W., & Haussler, M.R. (1983) The ovary: a target organ for 1,25 dihydroxycholecalciferol D3. *Endocrinology* **112** (1) 200-6.

Drent, P.J. & Woldendorp, J.W. (1989) Acid rain and eggshells. *Nature*. **339**; 439.

Driggers, J.C. & Comar, C.L. (1949) The secretion of radioactive calcium (⁴⁵Ca) in the hen's egg. *Poultry Science* **28**:420-424.

Duff, S.R.I. & Thorp, B.H. (1985) Patterns of physiological bone torsion in pelvic appendicular skeletons of domestic fowl. *Research in Veterinary Science* **39**: 307-312.

Earle, K.E. & Clarke, N.R. (1991) The nutrition of the budgerigar (*Melopsittacus undulatus*). *Journal of Nutrition* **121**: 186-192.

Eastwell, R. (1999) Pathogenesis of Postmenopausal Osteoporosis In: *Primer on the Metabolic Bone diseases and Disorders of Mineral Metabolism*, (5th edition, M. J. Favus ed.), pp 260-262. Lippencott, Williams and Wilkins, Philadelphia.

Edwards, H.M. Jr. (1989) The effect of dietary cholecalciferol, 25 hydroxycholecalciferol and 1,25 dihydroxycholecalciferol on the development of tibial dyschondroplasia in broiler chickens in the absence and presence of disulfiram. *Journal of Nutrition* **119**: 647-652.

Edwards, H.M. Jr. (1990) Efficiency of several vitamin D compounds in the prevention of tibial dyschondroplasia in broiler chickens. *Journal of Nutrition* **120**: 1054-1061.

Edwards, H.M. Jr. (1992) Nutritional factors and leg disorders. In: *Bone biology and skeletal disorders in poultry* Poultry Science Symposium Number Twenty-three (C.C.Whitehead ed), pp 167-195. Carfax Publishing Company, Oxford.

Edwards, H.M. Jr., Elliot M.A., & Soonchareryning S. (1992) Effect of dietary calcium on tibial dyschondroplasia. Interaction with light, cholecalciferol, 1,25 dihydroxycholecalciferol, protein and synthetic zeolite. *Poultry Science* **71**(12) 2041-55.

Edwards, H.M. Jr., Elliot M.A., Soonchareryning, S. & Britton, W.M. (1994) Quantitive requirement for cholecalciferol in the absence of ultraviolet light. *Poultry Science* **73** (2): 288-94.

Edwards, H.M. Jr. (2000) Nutrition and skeletal problems in poultry. *Poultry Science* **79**(7): 1018-23.

Edwards, H.M. Jr., (2003) Effects of UVB irradiation of very young chickens on growth and bone development. *British Journal of Nutrition* **90** (1): 151-60.

Elaroussi, M.A. (1994) Calcium Homeostasis in the laying Hen. Age and Dietary Calcium Effects. *Poultry Science* **73**:1581-1589.

Elaroussi, M.A., Prahl, J.M. & Deluca, H.F. (1994) The avian vitamin D receptors: primary structures and their origins. *Proceedings of National Academy of Sciences, U S A.* **91** (24): 11596-600.

Eliam-Cisse, M.C., Taboulet, J., Bielakoff, J., Lasmoles, F., de Vernejoul, M.C. & Trielhou-Lahille, F. (1993) Influence of calcium and vitamin D deficient diet on calcitonin gene expression in the ultimobranhial cells of the developing chicken. *General Comparative Endocrinology* **89**(2): 195-205.

Elliot, M.A., Roberson, K.D., Rowland, G.N. & Edwards, H.M. Jr. (1995) Effects of dietary calcium and 1,25 dihydroxycholecalciferol on the development of tibial dyschondroplasia in broilers during the starter and growing periods. *Poultry Science* **74**(9): 1495-505.

Elliot, M.A. & Edwards, H.M. Jr. (1997) Effects of 1,25 dihydroxycholecalciferol, cholecalciferol and fluorescent lights on the development of tibial dyschondroplasia and rickets in broiler chickens. *Poultry Science* **76**(4): 570-80.

Etches, R.J. (1987) Calcium logistics in the laying hen. *Journal of Nutrition* **117**: 619-628.

Farquharson, C. & Jefferies, D. (2000) Chondrocyte and longitudinal bone growth: the development of tibial dyschondroplasia. *Poultry Science* **79**(7): 994-1004.

Feldman, D. & Malloy, P.J. (1990) Hereditary 1,25 dihydroxycholecalciferol resistant rickets: molecular basis and implications for the role of 1,25 dihydroxycholecalciferol in normal physiology. *Molecular and Cellular Endocrinology* **72**: C57- C62.

Ferguson, G. W., Gehrmann, W. H., Kjarsten, K. B., Hammack, S. H., McRae, M., Chen, T. C., Lung, N. P. & Holick, M. F. (2003) Do Panther chameleons bask to regulate endogenous vitamin D₃ production? *Physiological and Biochemical Zoology* **76** (1): 52 – 59.

Fiennes, R.N. (1974) Problems of rickets in monkeys and apes. *Proceedings of the Royal Society of Medicine* **67**: 309-314.

Forte L.R., Langeluttig, S.G., Poelling, R.E. & Thomas, M.L. (1982) Renal parathyroid hormone receptors in the chick: down regulation in secondary hyperparathyroid animal models. *American Journal of Physiology* **242**(3): E154-163.

Fowler, M.E. (1978) Metabolic Bone Disease. In: *Zoo and Wild Animal Medicine* (1st Edition, M.E. Fowler Ed), pp 55-76. W.B. Saunders, Philadelphia.

Fowler, M.E. (1981) Ossification of long bones in raptors. In: *Recent advances in the study of raptor diseases*, (J.E.Cooper, A.G.Greenwood eds), pp 75-82, Chiron Publications Keighley.

Fowler, M.E. (1986) Metabolic Bone Disease. In: *Zoo and Wild Animal Medicine* (3rd Edition, Fowler M.E. Ed), pp 63-82. W.B. Saunders, Philadelphia.

Fraser D.R. & Kodicek, E. (1973) Regulation of 25 hydroxycholecalciferol-1-hydroxylase by parathyroid hormone. *Nature New Biology* **241**: 163-166.

Fraser, D, Jones, G., Kooh, S.W. & Raddle, I. (1994) Calcium and Phosphorus Metabolism
In: *Textbook of Clinical Chemistry* (2nd edition. C.A. Burtis, E.R. Ashwood eds), W.B.
Saunders, Philadelphia.

Frederick, J.E., Snell, H.E. & Heywood, E.K. (1989) Solar ultraviolet radiation at the earth's
surface. *Photochemical Photobiology* **50**:443-450.

Freedman, M.T., Bush, M. & Novak, G.R. (1976) Nutritional and metabolic bone disease in
a zoological collection: A review of radiographic findings. *Skeletal Radiology* **1**: 87-96.

Friedmann, J. (1977) Tibial dyschondroplasia in broiler chickens. *Revue Veterinarian* **34**:149-
150.

Frost, T.J., Roland, D.A. Sr. & Marple, D.N. (1991) The effects of various dietary
phosphorus levels on circadian patterns of 1,25 dihydroxycholecalciferol, total calcium,
ionised calcium and phosphorus in laying hens. *Poultry Science* **70**(7): 1564-70.

Frost, T.J. & Roland, D.A. Sr. (1991) Research Note: current methods used in
determination and evaluation of tibia strength: a correlation study involving birds fed
different levels of cholecalciferol. *Poultry Science* **70** (7): 1640-3.

Gehrmann, W. H. (1996) Reptile lighting a current perspective. *The Vivarium* **8** (2): 44- 45.

Gilardi, J.D., Duffy, S.S., Munn, C.A. & Tell, L.A. (1999) Biochemical functions of geophagy
in parrots: detoxification of dietary toxins and cytoprotective effects. *Journal of Chemical
Ecology* **25**(4): 897-922.

Gionfriddo, J. P. & Best, L. B. (1995) Grit use by house sparrows: Effects of diet and grit
size. *Condor* **97**:57-67.

Goff, J.P. & Horst, R.L. (1995) Assessing adequacy of cholecalciferol supplementation in chickens using cholecalciferol metabolite concentrations as an indicator. *Journal of Nutrition* **125**(5): 1351-7.

Graveland, J. & Van Gijzen, T. (1994) Arthropods and seeds are not sufficient as calcium sources for shell formation and skeletal growth in passerines. *Ardea* **82**: 299-314.

Graveland, J. (1996) Avian eggshell formation in calcium rich and calcium poor habitats - importance of snail shells and anthropogenic calcium sources. *Canadian Journal of Zoology* **74**: 1035-1044.

Gray, T.K., McAdoo, T., Pool, D., Lester, G.E., Williams, M.E. & Jones, G. (1981) A modified radioimmunoassay for 1,25 dihydroxycholecalciferol. *Clinical Chemistry* **27**(3): 458-63.

Groth, W. (1962) Experimentelle untersuchungen uber calcium-und phosphat-mangel-osteopathien und ihre beziehung zur epithelkorperchenfunktion und zum mineralstoffgehalt des blutes bei wachsenden huhnren. *Zentralblatt fur Veterinarmedizin* **9**: 1009-1040.

Groth, W. & Frey, H. (1966) Zur differenzierung der wirkung eines mangels am calcium, phospor older vitamin D auf knochen, but und innersekretoische drusen des huhnerkukens. *Zentralblatt fur Veterinarmedizin* **13A**: 302-319.

Guglielmi, G. (2002) Quantitative Computed Tomography. *Seminars in Musculoskeletal Radiology* **6** (3) 21-227.

Hall, A.K. & Norman, A.W. (1990) Regulation of calbindin-D28K gene expression by 1,25 dihydroxyvitamin D3 in chick kidney. *Journal of Bone and Mineral Research* **5**(4): 325-330.

Hamburger, V. & Hamilton, H.L. (1951) A series of normal stages in the development of the chick embryo. *Journal of Morphology* **88**: 49-92.

Harcourt-Brown, N.H. (2003) Incidence of juvenile osteodystrophy in hand reared parrots (*Psittacus e. psittacus*). *The Veterinary Record* **152**: 438-439.

Harcourt-Brown, N.H. (2004) Development of the skeleton and feathers of dusky parrots (*Pionus fuscus*) in relationship to their behaviour. *The Veterinary Record* **154**: 42-48.

Hart, E.B., Halpin J.G. & Steenbock, H. (1922) The nutritional requirements of baby chicks: Further studies on leg weakness in chickens. *Journal of Biological Chemistry* **52**:379-386.

Hausmann, F., Arnold, K.E., Marshall, N.J. & Owens, I.P. (2003) Ultraviolet signals in birds are special. *Proceedings of The Royal Society of London Biological Sciences* **270** (1510): 61-7.

Hauschka, P.V., Lian, J.B., Cole, D.E. & Gundberg, C.M. (1989) Osteocalcin and matrix GLA protein; vitamin K-dependent protein in bone. *Physiology Review* **69**: 990-1034.

Hausler, M.R. (1986) Vitamin D receptors: Nature and Function. *Annual Review of Nutrition* **6**: 527-562.

Haye, U. & Simons, P.C.M. (1978) Twisted legs in broilers. *British Poultry Science* **19**: 549-557.

Henry, H.L. & Norman, A.W. (1978) Vitamin D: Two dihydroxylated metabolites are required for normal chick hatchability. *Science* **201**: 835-837.

Henry, H.L. (1985) Parathyroid Hormone modulation of 25 hydroxycholecalciferol metabolism by cultured chick kidney cells is mimicked and enhanced by forskolin. *Endocrinology* **116**: 503-510.

Hess, A., Pappenheimer, A.M. & Weinstock, M. (1922) A study of light waves in relation to their protective action in rickets. *Proceedings of Society of Experimental Biological Medicine* **20**: 1416.

Hess, L., Mauldin, G. & Rosenthal, K. (2002) Estimated nutrient content of diets commonly fed to pet birds. *The Veterinary Record* **150**: 399-403.

Hiernaux J., Rudan, P. & Brambuti, A. (1975) Climate and the weight/height relationship in sub-Saharan Africa. *Annals of Human Biology*

Hochleithner, M. (1989) Convulsions in African Grey parrots in connection with hypocalcaemia: Five selected cases. *Proceedings 2nd European Symposium Avian Medicine and Surgery*, pp44-52.

Hochleithner, M., Hochleithner, C. & Harrison, G.L. (1997) Evidence of Hypoparathyroidism in hypocalcaemic African Grey Parrots. *The Avian Examiner special supplement spring* (HBD International Ltd).

Holick, M.F., Adams, J.S. & Clemens, T.L. (1982) Photoendocrinology of vitamin D₃: the past, present and future. In: *Vitamin D, Chemical, Biochemical and clinical endocrinology of calcium metabolism*. (A.W. Norman, K. Schaefer, D.V. Herrath eds.), pp 1151-1156. Walter de Gruyter, Berlin.

Holick, M.F., Smith, E. & Pincus, S. (1987) Skin as a site of vitamin D₃ synthesis and target tissue for 1,25 dihydroxycholecalciferol; Use of calcitrol for the treatment of psoriasis. *Archives of Dermatology* **123**: 1677-1683.

Holick, M.F., Matsuoka, L.Y. & Wortsman, J. (1989) Age, vitamin D₃ and solar ultraviolet radiation. *The Lancet* **4**: 1104-1105.

Holick, M.F. (1989) Phytogetic and evolutionary aspects of vitamin D₃ from phytoplankton to humans. In: *Vertebrate Endocrinology: Fundamentals and Biochemical implications* (P.T. Pang, and Schreibman eds), pp 7-44. Academic press, New York.

Holick, M.F. (1994) Vitamin D₃: new horizons for the 21st century. *American Journal of Clinical Nutrition* **60**: 619-630.

Holick, M.F. (1995) Vitamin D₃: photobiology, metabolism and clinical applications. In: *Endocrinology* (3rd edition, L. DeGroot, H. Besser & H.G. Berger, eds), pp 990-1013. W.B. Saunders, Philadelphia.

Holick, M. F. (1999) Vitamin D₃: Photobiology, metabolism, mechanisms of action and clinical applications. In: *Primer on the metabolic bone diseases and disorders of mineral metabolism*. (M.J. Flavus ed), pp 92-98. Lippencott, Williams and Wilkins, Philadelphia.

Hollis, B.W., Kamerud, J.Q., Selvaag, S.R., Lorenz, J.D. & Napoli, J.L. (1993) Determination of vitamin D status by radioimmune assay with a 125 I-labelled tracer. *Clinical Chemistry* **52**:529-532.

Hollis, B.W., Kamerud, J.Q., Kurkowski, A., Beaulieu, J. & Napoli J.L. (1995) Quantification of circulating 1,25 dihydroxycholecalciferol by radioimmune assay with a 125 I-labelled tracer. *Clinical Chemistry* **42**:586-592.

Hollis, B.W., Clemens, T.L. & Adams, J.S. (1999) Vitamin D₃ metabolites. In: *Primer on the metabolic bone diseases and disorders of mineral metabolism*. (M.J. Flavus ed), pp124-128. Lippincott, Williams and Wilkins, Philadelphia.

Horst, R.L., Littledyke, E.T., Riley, J.L. & Napoli, J.T. (1981) Quantitation of vitamin D₃ and its metabolites and their plasma concentrations in 5 species of animal. *Analytical Biochemistry* **116**: 189-203.

Horst, R.L. & Littledyke, E.T. (1982) Comparison of plasma concentrations of vitamin D₃ and its metabolites in young and aged animals. *Comparative Biochemistry and Physiology* **73(3)**: 485-9.

Howard, L.L., Kass, P.H., Lamberski, N. & Wack, R.F. (2004) Serum concentrations of ionised calcium, vitamin D₃ and parathyroid hormone in captive thick billed parrots (*Rhynchopsitta Pachyrhyncha*). *Journal of Zoo and Wildlife Medicine* **35(2)**: 147-153.

Howell, J.M. & Thompson, J.N. (1967) Lesions associated with ataxia in Vitamin A deficient chicks. *British Journal of Nutrition* **21**: 741-750.

Howlett, C.R. (1978) The fine structure of the proximal growth plate of the avian tibia. *Journal of Anatomy* **128**: 377-399.

Hoy, D.A., Ramberg, C.F. Jr. & Horst R.L. (1988) Evidence that discrimination against ergocalciferol by the chick is the result of enhanced metabolic clearance rates for its mono and dihydroxylated metabolites. *Journal of Nutrition* **118**: 633-638.

Hurwitz, S., Harrison, H.C. & Harrison, H.E. (1967) Comparison of the actions of vitamin D₂ and vitamin D₃ in the chick with their retention in serum, liver and intestinal mucosa. *Journal of Nutrition* **91**: 208-212.

Hurwitz, S., Stacey, R.E. & Bronner, F. (1969) Role of vitamin D in Calcium regulation. *American Journal of Physiology* **216**: 254-262.

Hurwitz, S. (1989) Calcium homeostasis in birds. *Vitamins and Hormones* **45**: 173-221.

Hurwitz, S. & Pines, M. (1991) Regulation of bone growth. In: *Vertebrate Endocrinology: Fundamentals and Biochemical Implications* (P.K.T. Pang, M. Schreiber M, eds), pp 229-35. Academic Press, New York.

Hurwitz, S., Plavnik, I., Shapiro, A., Wax, E., Talpaz, H. & Bar, A. (1995) Calcium metabolism and requirements of chickens are affected by growth. *Journal of Nutrition* **125** (10): 2679-86.

Ibanez, R. (2003) Bone mineral density measurement techniques. *An Sist Sanar Navar* **26**, 19-27.

Iwamoto, M., Sato K., Nakashima K., Shimazu A. & Kato Y. (1989) Hypertrophy and calcification of rabbit permanent chondrocytes in pellet cultures: Synthesis of alkaline phosphatase and 1,25 dihydroxycholecalciferol receptor. *Developmental Biology* **136**:500-508.

Jand, S.S., Tolnai, S. & Lawson, D.E.M. (1981) Immunochemical localisation of vitamin D-dependent calcium binding protein in duodenum, kidney, uterus and cerebellum of chickens. *Histochemistry* **71**: 99-116.

Johnston, P.M. & Comar, C.L. (1955) Distribution and contribution of calcium to albumen, yolk and shell to the developing chick embryo. *American Journal of Physiology* **183**: 365-370.

Johnson, M. S. & Ivey, E. S. (2002) Parathyroid and Ultimobranchial Glands: Calcium metabolism in birds. In: *Seminars in avian and exotic pet medicine* (A. M. Fudge & N. Antinoff eds), (11) **2**: 84 – 94. W.B. Saunders Company, Philadelphia.

Jones, E.K., Prescott, N.B., Cook, P., White, R.P. & Wathes, C.M. (2001) Ultraviolet light and mating behaviour in domestic broiler breeders. *British Poultry Science* **42** (1): 23-32.

Jones, R. L. & Hanson, H. C. (1985) Mineral Licks, Geophagy, and Biogeochemistry of North American Ungulates. The Iowa State University Press, Ames, Iowa.

Julian, R. (1984) Valgus-varus deformity of the intertarsal joint in broiler chickens. *Canadian Veterinary Journal* **25**:254-258.

Juppner, H., Brown, E.M. & Kronenberg, H.M. (1999) In: *Primer on the Metabolic Bone Disease and Disorders of Bone Metabolism*. (5th edition, M. J. Favus ed.), pp 80-87. Lippencott, Williams and Wilkins, Philadelphia.

Kallet, A.J., Richter, K.P. Feldman, E.C. & Brum, D.E. (1991) Primary hyperparathyroidism in cats: seven cases (1984-1989). *Journal of the American Veterinary Medical Association* **199**: 1767-1771.

Kemper, N.F., Duignan, P.J., Kirkwood, J.E., Bennet, P.M. & Price, D.J. (1990) Comparative cell kinetics of avian growth plates. *Research in Veterinary Science* **49**: 283-288.

Kenny, A.D. & Dacke, C.G. (1974) The hypercalcaemic response to parathyroid hormone in the Japanese quail. *Journal of Endocrinology* **62**: 15-23.

Kenny, A.D. (1986) Parathyroid and ultimobranchial glands. In: *Avian Physiology* (4th edition P.D. Sturkie ed), pp 466-478. Springer-Verlag, New York.

Kestin, S.C., Su, G. & Sorensen, P. (1999). Different commercial broiler crosses have different susceptibilities to leg weakness. *Poultry Science* **78**: 1085-1090.

Khosla, S., Demay, M., Pines, M., Hurwitz, S., Potts, J.T. Jr. & Kronenberg, H.M. (1988) Nucleotide sequence of cloned cDNAs encoding chicken preproparathyroid hormone. *Journal of Bone and Mineral Research* **3**:689-698.

Kiiskinen, T. & Anderson, P. (1982) The incidence of tibial dyschondroplasia in two broiler strains and there performance on two different diets. *Annales Agriculturae Fenniae* **21**: 169-176.

Kirby, G.C. & Dacke, C.G. (1983) Hypercalcaemic response to 16,16 dimethyl prostaglandin E₂, a stable prostaglandin E₂ analogue, in chickens. *Journal of Endocrinology* **99**:115-122.

Kirkwood, J.E., Duignan, P.J., Kemper, N.F., Bennet, P.M. & Price, D.J. (1989) The growth rate of the tarsometatarsus of birds. *Journal of the Zoological Society of London* **217**: 403-416.

Klasing, K.C. (1998) Minerals In: *Comparative Avian Nutrition* (K.C. Klasing ed), pp 290-295. CAB International, New York.

Klein, D.C. & Raisz, L.G. (1970) Prostaglandins: stimulation of bone resorption in tissue culture. *Endocrinology* **86**: 1436-1440.

Klein, G.L. & Chesney, R.W. (1986) Metabolic bone disease associated with total parental nutrition. In: *Total parental nutrition: indication, utilisation, complications and pathological considerations*, (E.Lebenthal ed.), pp 431-443. Raven Press, New York.

Klein, G.L. & Simmons, D.J. (1993) Nutritional rickets: thoughts on pathogenesis. *Annals of Medicine* **25**: 379-386.

Knowles, T.G. & Broom, D.M. (1990) Limb bone strength and movement in laying hens from different housing systems. *The Veterinary Record* **126**: 354-356.

Koch, E.M. & Koch, F.C. (1941) The provitamin of covering tissues of chickens. *Poultry Science* **20**: 33-35.

Koch, J., Wideman, R.F. & Bush, E.G. (1984) Blood ionic calcium response to hypocalcaemia in the chicken induced by ethylene glycol-bis- (B-aminoethylether)-N, N'-tetraacetic acid: Role of the parathyroids. *Poultry Science* **63**: 167-171.

Kostka, V., Krautwald, M.E., Tellhelm, B. & Schildger, B. (1988) A contribution to radiological examination of bone alterations in psittacines, birds of prey and pigeons. *Proceedings of the Association of Avian Veterinarians. Lake Worth, USA*, pp 37-59.

Koutsos, E.A., Matson, K.D. & Klasing, K.C. (2001) Nutrition of birds in the order Psittaciformes. *Journal of Avian Medicine and Surgery* **15**:257-275.

Koutsos, E.A., Tell, L.A., Woods, L.W. & Klasing, K.C. (2003) Adult cockatiels (*Nymphicus hollandicus*) at maintenance are diets. *Journal of Nutrition* **113(6)**: 1898-902.

Kratser, F.H. & Vohra, P. (1986) Chelates in animal nutrition. CRC press, Boca Raton.

Kriajev, L. & Edelstein, S. (1994) 24,25 dihydroxycholecalciferol antagonises some of the actions of 1,25 dihydroxycholecalciferol. *Biochemical and Biophysical Research Communications* **202 (3)**: 1204-8.

Kumar, R. (1984) Metabolism of 1,25 dihydroxyvitamin D₃. *Physical Review* **64(2)**: 478-504.

Ladenson, J.H., Lewis, J.W. & Boyd, J.C. (1978) Failure of calcium corrected for protein, albumin and pH to correctly assess free calcium status. *Journal of Clinical Endocrinology and Metabolism* **11**: 986-993.

Leeson, S. & Summers, J.D. (1988) Some nutritional implications of leg problems with poultry. *British Veterinary Journal* **144**:81-92.

Lewis, P.D., Perry, G.C. & Morris, T.R. (2000) Ultraviolet radiation and laying pullets. *British Poultry Science* **41** (2): 131-5.

Lim, S.K., Gardella, T., Thompson, A., Rosenberg, J., Keutmann, H., Potts, J., Kroneberg, H. & Nussbaum, S. (1991) Full length chicken parathyroid hormone: Biosynthesis in *Escherichia coli* and analysis of biological activity. *Journal of Biological Chemistry* **266**: 3709-3714.

Logan, T. (1969) Experiments with gro-lux light and its effects on reptiles. *International Zoo Year Book* **9**: 9-11.

Long, P.H., Lee, S.R., Rowland, G.N. & Britton, W.M. (1984) Experimental rickets in broilers: gross, microscopic and radiographic lesions. III. Vitamin D deficiency. *Avian Diseases* **28**: 933-943.

Loveridge, N., Thomson, B.M. & Farquharson, C. (1992) Bone growth and turnover. In: *Bone Biology and Skeletal Disorders in Poultry. Poultry Science Symposium Number Twenty-three* (C.C. Whitehead ed.), pp3-11. Carfax Publishing Company, Oxford.

Lu, Z., Jehan, F., Zierold, C. & Deluca, H.F. (2000) Isolation and characterisation of the chicken vitamin D receptor gene and its promoter. *Journal of Cell Biochemistry* **77** (1): 92-102.

Luck, M.R & Scanes, C.G. (1979) The relationship between reproductive activity and blood calcium in the calcium deficient hen. *British Poultry Science* **20**(6): 559-64.

Lumeij, J.T. de Bruijne, J.J. & Kwant, M.M. (1989) Comparative total protein and albumin determinations in pigeon sera. *Avian Pathology* **19**: 255-261.

Lumeij, J.T. (1990) Relationship of plasma calcium to total protein and albumin in grey (*Psittacus e erithacus*) and Amazon (*Amazona spp.*) parrots. *Avian Pathology* **19**: 661-667.

Lumeij, J.T., Remple, J.D. & Riddle, K.E. (1993) Relationship of plasma total protein and albumin to total calcium in peregrine falcons (*Falco peregrinus*). *Avian Pathology* **22**: 183-188.

Mac-Auliffe, T. & McGinnis, J. (1976) Effect of ultraviolet light and oral vitamin D3 on rachitic chicks fed diets containing either corn or rye. *Poultry Science* **55** (6): 2305-9.

MacLaughlin, J.A., Anderson, R.R. & Holick, M.F. (1982) Spectral character of sunlight modulates photosynthesis of pre. vitamin D and its photoisomers in human skin. *Science* **216**:1001-1003.

MacWhirter, P. (1994) Malnutrition. In: *Avian Medicine: Principles and Application*, (Ritchie B.W., Harrison G.J. and Harrison L.R. eds), pp 842-861, Wingers Publishing, Lake Worth, Florida.

McChesney, E.W. (1943) Studies of calcium and phosphorus metabolism in the chick. I. The comparative effect of vitamin D2 and D3 and dihydrotachysterol given orally and intramuscularly. *Journal of Nutrition* 1943; **103**:81-94.

McDonald, L.J. (1988) Hypocalcaemic seizures in an African Grey parrot. *Canadian Veterinary Journal* **29**:928-930.

McSheehy, P.M.J. & Chambers, T.J. (1986) Osteoblast-like cells in the presence of parathyroid hormone release soluble factor that stimulates osteoclastic bone resorption. *Endocrinology* **119**: 1654-1659.

Mahaney, W. C., Hancock, R. G. V., Aufreiter, S. & Huffmann, M. A. (1996) Geochemistry and clay mineralogy of termite mound soil and the role of geophagy in chimpanzees of the manhale mountains, Tanzania. *Primates* **37(2)**: 121-134.

Marlow, R. W., & Tollesrup, K. (1982) Mining and exploitation of natural mineral deposits by the desert tortoise (*Gopherus agassizii*). *Animal Behaviour* **30**:475-478.

Massengale, O.N.& Nussmeier, M. (1930) The action of activated ergosterol in the chicken. *Journal of Biological Chemistry* **87**: 423-425.

Mattila, P., Lehtikoinen, K., Kiiskinen, T. & Piironen, V. (1999) Cholecalciferol and 25-hydroxycholecalciferol content of chicken egg yolk as affected by the cholecalciferol content of feed. *Journal of Agriculture and Food Chemistry* **47 (10)**: 4089-92.

Mattila, P., Rokka, T., Konko, K., Valaja, J., Rossow, L. & Ryhanen, E.L. (2003) Effect of cholecalciferol-enriched hen feed on egg quality. *Journal of Agriculture and Food Chemistry* **51 (1)**: 283-7.

Mayel-Afshar, S., Lane, S.M. & Lawson, D.E.M. (1988) Relationship between the levels of calbindin synthesis and calbindin mRNA. *Journal of Biological Chemistry* **263**: 4355-4361.

May, D.I. (1996) The behaviour of grey parrots in the rainforest of the Central African Republic. *Psittascene* **8(3)**: 8-9.

Miller, R.M. (1971) Nutritional secondary hyperparathyroidism in monkeys. In: *Current Veterinary Therapy* (Edition IV, R.W. Kirk ed.), pp407-408. W.B. Saunders, Philadelphia.

Miller, S.C. (1977) Osteoclast cell-surface changes during the egg laying cycle in Japanese quail. *Journal of Cell Biology* **75**: 104-118.

Miller, P.D., Bonnick, S.L. & Rosen, C.J. (1996) Clinical utility of bone mass measurements in adults: consensus of an international panel. *Seminars in Arthritis and Rheumatology* **25**: 361-372.

Mitchell, R.D., Edwards, H.M. Jr. & MacDaniel, G.R. (1997a) The effects of ultraviolet light and cholecalciferol and its metabolites on the development of leg abnormalities in chickens genetically selected for a high and low incidence of tibial dyschondroplasia. *Poultry Science* **76** (2): 346-54.

Mitchell, R.D., Edwards, H.M. Jr., McDaniel, G.R. & Rowland, G.N. (1997b) Dietary 1,25 dihydroxycholecalciferol has variable effects on the incidences of leg abnormalities, plasma vitamin D metabolites, and vitamin D receptors divergently selected for tibial dyschondroplasia. *Poultry Science* **76**(2): 338-45.

Mitchell, H.H., Kendall, F.E. & Card, L.E. (1923) The vitamin requirements of growing chickens. *Poultry Science* **2**: 117-124.

Mitchell, M. (2002) Determination of Plasma Biochemistries, ionised calcium, vitamin D3 and haematocrit values in Captive Green Iguanas (*Iguana iguana*). *Proceedings of the Association of Reptile and Amphibian Veterinarians 9th Annual Conference*, pp 87-95.

Morrissey, R.L., Cohn, R.M., Empson, R.N. Jr., Greene, H.L. & Tauton, O.D. (1977) Relative toxicity and metabolic effects of cholecalciferol and 25 hydroxycholecalciferol in chicks. *Journal of Nutrition* **107**(6): 1027-34.

Munn, C. A. (1992) Macaw biology and ecotourism, or "when a bird in the bush is worth two in the hand" In: *New World Parrots in Crisis* (S. R. Beissinger & N. F. R. Snyder eds.), pp 47-72. Smithsonian Institution Press, Washington, D.C.

Murphy, T.P., Wright, K.E. & Pudelkiewicz, W.J. (1981) An Apparent rachitogenic effect of excessive vitamin E intakes in the chick. *Poultry Science* **60**: 1873-1878.

Narbaitz, R. & Tsang, C.P. (1989) Vitamin D deficiency in the chick embryo: effects on prehatching motility and on growth and differentiation of bones, muscles and parathyroid glands. *Calcifying Tissue International* **44 (5)**: 348-55.

National Research Council (1994) *Nutrient Requirements of Poultry*. National Academy Press, Washington DC., U.S.A.

Nemere, I. & Norman, A.W. (1991) Transport of calcium. In: *Handbook of physiology*, pp. 337-360. American Physiological Society, Bethesda, Maryland, U.S.A.

Nemere, I. (1996) Parathyroid hormone rapidly stimulates phosphate transport in perfused duodenal loops of chicks: lack of modulation by vitamin D metabolites. *Endocrinology* **137 (9)**: 3750-5.

Nemere, I. (1999) 24,25 dihydroxycholecalciferol D3 suppresses the rapid actions of 1,25 dihydroxycholecalciferol and parathyroid hormone on calcium metabolism in chick intestine. *Journal of Bone and Mineral Research* **14 (9)**: 1543-9.

Nevalainen, T. (1969) Fine structure of the parathyroid gland of the laying hen (*Gallus domesticus*). *General and Comparative Endocrinology* **12**:561-567.

Nissenson, R.A., & Arnaud, C.D. (1979) Properties of the parathyroid receptor-adenylate cyclase system in chicken renal plasma membrane. *Journal of Biological Chemistry* **254**:1469-1475.

Norman, A.W. (1987) Studies on the vitamin D endocrine system in the avian. *Journal of Nutrition* **117 (4)**: 797-807.

Norman, A.W. (1990) The avian as an animal model for the study of the vitamin D endocrine system. *Journal of Experimental Zoology*. **4 (Suppl)**: 37-45.

Norman, A.W. & Hurwitz, S. (1993) The role of the vitamin D endocrine system in avian bone biology. *Journal of Nutrition* **123 (2 Suppl)**: 310-316.

Nys, Y. (1993) Regulation of plasma 1,25 dihydroxycholecalciferol of osteocalcin and of intestinal and uterine calbindin in hens. In: *Avian Endocrinology*, (P.J. Sharp ed.), pp345-357. *Journal of Endocrinology Ltd*, Bristol, U.K.

Okada, K., Fujimoto, Y., Itakura, C. & Goto, M. (1983) Ultrastructure of parathyroid glands of growing chicks with vitamin D deficiency rickets. *American Journal of Veterinary Research* **44 (4)**: 697-704.

Oken, L. (1837) *Allgemine Naturgeschichte fur all stande*; Bd. 7 Abt.1. Hoffmann'sche Verlagsbuchlandlung, Stuttgart.

Olsen, W.G., Dziuk, H.E., Walser, M.M., Hanlon, G.F., Waibel, P.E., Stevens, J.B. & Jorgensen, N.A. (1981) Field rickets in turkey poults: biochemical findings. *Avian diseases* **25**:550-554.

Omdahl, J.L. & Deluca, H.F. (1973) Regulation of vitamin D metabolism and function. *Physiological Review* **53**: 327-372.

O'Riordan, J.L.H. (1997) Rickets, from history to molecular biology, from monkeys to YACS. *Journal of Endocrinology* **154**: S3-S13.

Ornoy, A., Goodwin, D., Noff, D. & Edelstein, S. (1978) 24,25- dihydroxycholecalciferol is a metabolite of vitamin D essential for bone formation. *Nature* **276**: 517-519.

Pallauf, J. & Rimbach, G. (1997) Nutritional significance of phytic acid and phytase. *Arch Tierernahr* **50 (4)**: 301-319.

Pearn, S.M., Bennett, A.T. & Cuthill, I.C. (2001) Ultraviolet vision, fluorescence and mate choice in a parrot, the budgerigar (*Melopsittacus undulatus*). *Proceedings of Royal Society London Biological Science* **7**: 268 (1482): 2273-9.

Pendergast, B. A., & Boag, D. A. (1970) Seasonal changes in diet of spruce grouse in central Alberta. *Journal of Wildlife Management* **34(3)**: 605-611.

Peterson, M.E., James, K.M., Wallace, M., Timothy, S.D. & Joseph, R.J. (1991) Idiopathic hypoparathyroidism in five cats. *Journal of Veterinary Internal Medicine*. **5**: 47-51.

Pierson, F.W. & Hester, P.Y. (1982) Factors influencing leg abnormalities in poultry: A review. *World's Poultry Science Journal* **38**:5-17.

Pines, M., Bar, A. & Hurwitz, S. (1984) Isolation and purification of avian parathyroid hormone using a high performance liquid chromatography, and some of its properties. *General Comparative Endocrinology* **53 (2)**: 224-31.

Pines, M., Yarden, N, Ben-Basset S., Lavelin, I. & Leach R.M. (1999). Regulation of the calcium sensing and parathyroid receptor genes in the chick. In: *Calcium metabolism*:

Comparative Endocrinology (J. Danks, C. Dacke, G. Flik & C. Gay eds), pp 67-74.
Bioscientifica Ltd, Bristol, UK.

Portale, A.A. (1999) Blood calcium, phosphorus and magnesium. In: *Primer on the metabolic bone diseases and disorders of mineral metabolism*, (M.J.Flavus ed), pp 115-118. Lippincott, Williams and Wilkins.

Prasad, S., Hairr, W.T. & Dallas, J.T. (1972) Observations of abnormal cartilage formation associated with leg weakness in commercial broilers. *Avian Diseases* **16**: 457-461.

Price, J.S., Jackson, B. & Eastell, R. (1995) Age related changes in biochemical markers of bone metabolism in horses. *Equine Veterinary Journal* **27**: 201-207.

Pryce, E. (1994) Grey lorries (*Corythaixoides concolor*) feeding on clay. *Babbler* **26-27**: 23-24.

Qin, X. & Klandorf, H. (1993) Effect of oestrogen in relation to dietary vitamin D3 and calcium on activity of intestinal alkaline phosphatase and Ca-ATPase in immature chicks. *General Comparative Endocrinology* **90 (3)**: 318-327.

Rambeck, W.A., Weiser, H., Meier, W. & Zucker, H. (1988) Synergistic effects of vitamin D metabolites. *Annals of Nutrition and Metabolism* **32 (2)**: 108-11.

Randall, C.J. & Mills, C.P.J. (1981) Observations on leg deformities in broilers with particular reference to the intertarsal joint. *Avian Pathology* **10**: 407-431.

Randell, M.G. (1981) Nutritionally induced hypocalcaemic tetany in an Amazon parrot. *Journal of American Veterinary Medical Association* **179 (111)**: 1277-8.

Ravin, P., Clemmesen, B. & Christiansen, C. (1999) Biochemical markers can predict the response in bone mass during alendronate treatment in early postmenopausal women. *Bone* **24**: 237-244.

Reichel, H., Koeffler, H.P. & Norman, A.W. (1989) The role of the vitamin D endocrine system in health and disease. *New England Journal of Medicine* **320**: 980-991.

Reiland, S., Olssen S.E., Poulos, P.W. & Elwinger, K. (1978) Normal and pathological skeletal development in broiler and leghorn chickens. *Acta Radiologica* **358 (suppl)**: 277-298.

Rennie, J.S., McCormack, H.A., Farquharson, C., Berry, J.L., Mawer, E.B. & Whitehead, C.C. (1995) Interaction between dietary 1,25 dihydroxycholecalciferol and calcium and effects of management on the occurrence of tibial dyschondroplasia, leg abnormalities and performance in broiler chickens. *British Poultry Science* **36(3)**: 465-77.

Rennie, J.S., Fleming, R.H., McCormack, H.A., McCorquodale, C.C. & Whitehead, C.C. (1997) Studies on effects of nutritional factors on bone structure and osteoporosis in laying hens. *British Poultry Science* **38(4)**: 417-24.

Richardson, P.R.K., Mundy, P.J. & Plug, I. (1986) Bone crushing carnivores and their significance to osteodystrophy in griffon vulture chicks. *Journal of Zoology* **210**: 23-43.

Ricklefs, R.E, Starck, J.M.& Konarezewski, M. (1998) Internal constraints on growth in birds. In: *Avian growth and development. Evolution within the altricial-precocial spectrum*, (J.M. Stark, R.E. Ricklefs eds), pp 226-287. Oxford University Press, Oxford.

Riddell, C. (1981) Skeletal deformities in poultry. *Advances in Veterinary Science and Comparative Medicine* **25**: 277-310.

Riddell, C. & Pass, D.A. (1981) The influence of dietary calcium and phosphorus on tibia dyschondroplasia in broiler chickens. *Avian diseases* **31**:771-775.

Riddel, C. & Springer, R. (1985) An epizootiological study of acute death syndrome and leg weakness in broiler chickens in western Canada. *Avian Diseases* **29**:90-102.

Riddel, C. (1991) Developmental, metabolic and miscellaneous disorders. In: *Diseases of poultry* (9th edition, B.W.Calnek, H.J. Barnes, W.W. Beard, W.M. Reid, H.W.Yoder Jr., eds), pp 827-862. Iowa State University Press, Ames, Iowa.

Riddell, C. (1992) In: *Bone biology and skeletal disorders in poultry*, Poultry Science Symposium Number Twenty-three, (C.C. Whitehead, Ed), pp 137-141 Carfax Publishing Company, Oxford.

Robben, J.H. & Lumeij, J.T. (1989) A comparison of parrot food commercially available in the Netherlands. *Tijdschr Diergeneeskde* **114** (1): 19-25.

Rose, N., Constantin, P. & Leterrier, C. (1996) Sex differences in bone growth in broiler chickens. *Growth Development Aging* **60**(2): 49-59.

Rosenberg, R., Hurwitz, S. & Bar, A. (1986) Regulation of kidney calcium binding protein in the birds (*Gallus domesticus*). *Comparative Biochemistry and Physiology* **83A**: 277-281.

Roset, K. & Phlaen, D.N. (2000) Determination of safe and adequate dietary calcium and vitamin D3 concentrations in a companion parrot. *Proceedings of Association of Avian Veterinarians*, Portland, pp 239-242.

Roskopf, W.J., Woerpel, R.W., Yanoff, S.R., Howard, E.B. & Britt, J.O. (1981) Dietary induced parathyroid hyperplasia in a macaw. *Modern Veterinary Practice* 1981 **62**(10): 778-779.

Roskopf, W.J.& Woerpel, R.W. (1984) Egg binding in caged and aviary birds. *Modern Veterinary Practice* **65(6)**: 437-40.

Roskopf, W.J., Woerpel, R.W.& Lane, R.A., (1985) The hypocalcaemic syndrome in African Greys: An updated clinical viewpoint. *Proceedings Association of Avian Veterinarians*, pp 129-132.

Roudebush, P. (2000) In: *Small Animal Clinical Nutrition* (4th edition S.H. Hand, C.D. Thatcher C.D. eds), pp 943-1001. Mark Morris Institute, Kansas, USA.

Roudybush, T.E. (1996) Nutrition. In: *Diseases of Cage and Aviary Birds*, (W.Roskopf, R. Worpel eds.) pp, 218-234. Williams and Wilkins, Baltimore.

Roudybush, T.E. (1999) Psittacine Nutrition. *Veterinary Clinics North American Exotic Animal Practice* **2 (1)**: 111-25.

Russell, J. & Sherwood, L.M. (1989) Nucleotide sequence of the DNA complementary to avian (chicken) parathyroid hormone mRNA and the deduced sequence of the hormone precursor. *Molecular Endocrinology* **3**: 325-331.

Sailaja, R., Kotak, V.C., Sharp, P.J., Schmedemann, R. & Haase, E. (1988) Environmental, dietary and hormonal factors in the regulation of seasonal breeding in free-living female Indian rose-ringed parakeets (*Psittacula krameri*). *Hormone and Behaviour* **22(4)**: 518-27.

Sauveur, B. (1984) Dietary factors as cause of leg abnormalities in poultry – A review. *World Poultry Science Journal* **40**:195-206.

Sauveur, B. (1986) A further review of some dietary abnormalities controlling leg abnormalities in poultry. *World's Poultry Science Journal* **42**: 280-288.

Schenck, P.A., Chew, D.J. & Brooks, C.L. (1995) Effects of storage on serum ionised calcium and pH values in clinically normal dogs. *American Journal of Veterinary Research* **56**, 304-307.

Schermer, D.T., Chan, S.D.H., Bruce, R., Nissenson, R.A., Wood, W.I. & Strewler, G.J. (1991) Chicken parathyroid hormone –related protein and its expression during embryonic development. *Journal of Bone and Mineral Research* **6**: 149-155.

Schoemaker, N.J., Lumeij, J.T., Dorrestein, G.M.& Beynen, A.C. (1999) Nutrition-related problems in pet birds. *Tijdschr Diergeneeskd* **124(2)**: 39-43.

Schweitzer, M.H., Wittmeyer, J.L. & Horner, J.R (2005) Gender specific reproductive tissue in ratites and *Tyrannosaurus rex*. *Science* **308**: 1456-1459.

Shane, E. (1999) Hypocalcaemia: Pathogenesis, differential diagnosis and management. In: *Primer on the metabolic bone diseases and disorders of mineral metabolism*. (M.J. Flavus ed), pp 223-226. Lippencott, Williams and Wilkins, Philadelphia, U.S.A.

Simkiss, K. (1975) Calcium metabolism and avian reproduction. Symposium of The Zoological Society (London) **36**: 321-367.

Singh, R., Joyner, C.J., Peddie, M.J.& Taylor, T.G. (1986) Changes in parathyroid hormone and ionic calcium in the plasma of laying hens in relation to dietary deficiencies of calcium and vitamin D. *General Comparative Endocrinology* **66**: 381-386.

Soares, J.H., Kaetzel, D.M., Allen, J.T. & Swerdel, M.R. (1983) Toxicity of a vitamin D₃ steroid to laying hens. *Poultry Science* **62 (1)**: 24-9.

Soares, J.H. Jr. (1984) Calcium metabolism and its control – a review. *Poultry Science* **63(10)**: 2075-83.

Soares, J.H. Jr., Kerr, J.M. & Gray, R.W. (1995) 25 hydroxycholecalciferol in poultry nutrition. *Poultry Science* **74**(12): 1919-34.

Soares, J.H. (1995) Calcium Bioavailability. In: *Bioavailability of nutrients for animals*, (C.B. Ammerman, D.H. Baker, A.J. Lewis, eds), pp 95-118. Academic Press, San Diego.

Sokol, O. M. (1971) Lithophagy and geophagy in reptiles. *Journal of Herpetology* **5**:69-71.

Sommerville, B.A., Swaminathan, R. & Scanes, C.G. (1977) The effects of dietary calcium and of oestrogen on the metabolism of 25 hydroxycholecalciferol in vitamin D replete chicks. *Calcifying Tissue Research* **22 Suppl**: 51-54.

Sommerville, B.A., Scanes, C.G., Swaminathan, R., Care, A.D., Harvey, S. & Chadwick, A. (1989) Effect of oestrogen on calcium homeostasis and pituitary hormones in the growing chick. *General Comparative Endocrinology* **76**(2): 261-6.

Spanos, E., Barrett, D.I., Chong, K.T. & MacIntyre, I. (1978) Effect of oestrogen and 1,25 dihydroxycholecalciferol on 25 hydroxycholecalciferol metabolism in primary chick kidney cell cultures. *Biochemistry Journal* **174**(1): 231-6.

Spaulding, K.E. & Loomis, M.R. (1999) Principals and Applications of Computed Tomography and Magnetic Resonance Imaging in Zoo and Wildlife Medicine. In: *Zoo and Wild Animal Medicine Current Therapy*. (4th Edition, M.E. Fowler, R.E. Miller eds), pp 63-78. WB Saunders, Philadelphia.

Stanford, M.D. (2001) The measurement of ionised calcium in grey parrots. In: *Proceedings of the British Veterinary Zoological Society Autumn meeting, Royal Veterinary College, Potters Bar, 10-11 November*, pp 21-24.

Stanford, M.D. (2002a) Development of a parathyroid hormone assay in grey parrots. In: *Proceedings of the British Veterinary Zoological Society Spring meeting Chester 11-12 May*, pp 37.

Stanford, M.D. (2002b) Determination of 25-hydroxyvitamin D in seed fed grey parrots. *Proceedings of Joint Nutritional Symposium, Antwerp, Belgium, 21-25 August*, pp 142-141.

Stanford, M.D. (2002c) Cage and aviary birds. In: *BSAVA Manual of Exotic Pets* (A. Meridith & S. Redrobe eds), pp 161. BSAVA publications, Gloucester, UK.

Stanford, M.D. (2003a) Measurement of ionised calcium in grey parrots (*Psittacus e. erithacus*): the effect of diet. *Proceedings of the European Association of Avian Veterinarians 7th European meeting, Tenerife, Spain April 22-26*, pp 269-275.

Stanford, M.D. (2003b) Measurement of 25-hydroxycholecalciferol in captive grey parrots (*Psittacus e erithacus*). *The Veterinary Record* **153**: 58-59.

Stanford, M.D. (2005a) Clinical pathology of hypocalcaemia in grey parrots. *Proceedings of The International Conference on Exotics 2005, Fort Lauderdale, Florida, US 7.2 Supplement*: 28-34.

Stanford, M.D. (2005b) Nutrition and nutritional disease. In: *BSAVA Manual of Psittacine Birds* (N.H. Harcourt-Brown & J. Chitty eds), pp 136-155. BSAVA publications, Gloucester, UK.

Stamp, T.C.B. (1975) Factors in human vitamin D nutrition and in the production and cure of classical rickets. *Proceedings of Nutritional Society, December*, **34**:119-130.

Stark, J.M. (1989) Zeitmuster der Ontogenesen bei nestfluchtenden und nesthockenden Vögeln. *Courier Forschungsinstitut Senckenberg* **114**: 1-318.

Stark, J.M. (1994) Quantitative design of the skeleton in bird hatchlings: Does tissue compartmentalisation limit post hatching growth rates? *Journal of Morphology* **222**:113-131.

Stark, J.M. & Ricklefs, R.E. (1998) The development of the skeleton. In: *Avian Growth and development evolution within the Altricial-precocial spectrum* (J.M. Stark, R.E. Ricklefs, eds), pp 64-74. Oxford University Press, Oxford.

Stark, J.M. (1996) Comparative morphology and cytokinetics of skeletal growth in hatchlings of altricial and precocial birds. *Zoologischer Anzeiger* **235**:53-75.

Stevens, V.I., Blair, R. & Riddell, C. (1983) Dietary levels of fat, calcium and vitamin A and D3 as contributory factors to rickets in poults. *Poultry Science* **62**: 2073-2082.

Suda, T., Shinki, T. & Takahashi, N. (1990) The role of vitamin D in bone and intestinal cell differentiation. *Annual Review of Nutrition* **10**: 195-211.

Suda, T., Shinki, T. & Kurokawa, K. (1994) The mechanisms of regulation of vitamin D metabolism in the kidney. *Current Opinion in Nephrology and Hypertension* **3**(1): 59-64.

Surai, P.F., Ionov, I.A., Kuklenko, T.V., Kostjuk, I.A., MacPherson, A., Speake, B.K., Noble, R.C. & Sparks, N.H.C. (1998) Effects of supplementing the hen's diet with vitamin A on the accumulation of vitamins A and E, ascorbic acid and carotenoids in the egg yolk and in the embryonic liver. *British Poultry Science* **39**: 257-263.

Surai, P.F. (2002) In: *Natural antioxidants in avian nutrition and reproduction*. (P.F. Surai ed), pp 92-96. Nottingham University Press, Nottingham.

Swarup, K., Tewari, N.P. & Srivastav, A.K. (1986) Ultimobranchial body and parathyroid of the parrot *Psittacula psittacula* in response to experimental hypercalcaemia. Arch Anat Microsc Morphol Exp. **75**(4): 271-7.

Takahashi, N., Abe, E., Tanabe, R. & Suda, T. (1980) A high affinity cytosol binding protein for 1- α -25 dihydroxycholecalciferol in the uterus of the Japanese quail. Biochemical Journal **190**: 513-518.

Takahashi, N., Shinki, T., Abe, E., Morinchi, N., Yamaguchi, A., Yoshiki, S. & Suda, T. (1983) The role of vitamin D in the medullary bone formation in the egg laying Japanese quails and in immature chicks treated with sex hormone. Calcifying Tissue International **35**:465-471.

Takechi, M. & Itakura, C (1995) Ultrastructural studies of the epiphyseal plate of chicks fed a vitamin D deficient and low calcium diet. Journal of Comparative Pathology **113**(2): 101-111.

Tanaka, Y. & Deluca, H.F. (1971) Bone mineral mobilisation activity of 1,25 dihydroxycholecalciferol, a metabolite of vitamin D₃. Archives of Biochemistry and Biophysics **146**: 574-578.

Tang, K., Rowland, G.N. & Veltman, J.R. Jr. (1984) Vitamin A toxicity: Comparative changes in the bone of the broiler and leghorn chicks. Avian Diseases **29**: 416-429.

Taylor, T.G. (1971) In: *Physiology and Biochemistry of Domestic Fowl* (D.J.Bell, B.M. Freeman, eds), pp 473-480. Academic Press, London, U.K.

Taylor, T.G. & Dacke, C.G. (1984) Calcium metabolism and its regulation. In: *Physiology and biochemistry of the Domestic Fowl Volume 5*, (B.M. Freeman ed), pp125-170. Academic Press, London, U.K.

Terry, M., Lanenga, M., McNaughton, J.L. & Stark, L.E. (1999) Safety of 25 hydroxycholecalciferol as a source of vitamin D₃ in the laying hen. *Veterinary Humeral Toxicology* **41(5)**: 312-316.

Theofan, G., Nguyen, A.P. & Normal, A.W. (1986) Regulation of calbindin- D28-K gene expression by 1,25 dihydroxycholecalciferol D₃ is correlated to receptor occupancy. *Journal of Biological Chemistry* **261 (36)**: 16943-7.

The WHO Study Group (1994) Assessment of fracture risk and its application to screening for postmenopausal osteoporosis. World Health Organisation, Geneva, Switzerland.

Thiede, M.A., Harm, S.C., McKee, R.L., Grasser, W.A., Duong, L.T. & Leach, R.M. (1990) Expression of the parathyroid hormone-related protein gene in the avian oviduct: potential role as a local modulator of vascular smooth muscle tension and shell gland motility during the egg laying cycle. *Endocrinology* **129**: 1958-1966.

Thorp, B.H. (1992) Abnormalities in the growth of leg bones In: *Bone biology and skeletal disorders in poultry*. Poultry Science Symposium Number Twenty-three (C.C. Whitehead ed), pp 147-167. Carfax Publishing Company, Oxford.

Tian, X.Q., Chen, T.C., Matsuoka, L.Y., Wortsman, J. & Holick, M.F. (1993) Kinetic and thermodynamic studies on the conversion of previtamin D₃ to vitamin D₃ in human skin. *Journal of Biological Chemistry* **268(20)**: 14888-92.

Tian, X.Q., Chen, T.C., Lu, Z., Shao, Q. & Holick, M.F. (1994a) Characterisation of the translocation process of vitamin D₃ from the skin into the circulation. *Endocrinology* **135 (2)**: 655-61.

Tian, X. Q., Chen, T. C. & Allen, M. (1994b) Photosynthesis of previtamin D₃ and its isomerisation to vitamin D₃ in the *Savanna monitor* lizard. In: *Vitamin D a pluripotent steroid hormone: Structural studies, molecular endocrinology and clinical applications*, (A. W. Norman, R. Bouillon, M. Thomasset. W. de Gruyter eds.), pp 893 – 894. Berlin, Germany.

Torrance, A.G. & Nachreiner, R. (1990) Human Parathyroid assay for use in dogs: Validation, sample handling studies and parathyroid function testing. *American Journal of Veterinary Research*. **50**:1193-1197.

Torrance, A.G. (1995) Disorders of Calcium Metabolism. In: *BSAVA Manual of Small Animal Endocrinology*, (A.G. Torrance, C.T.Mooney), pp 129-140. BSAVA publications, Cheltenham, U.K.

Tsang, C.P. & Grunder, A.A. (1993) Effect of dietary contents of cholecalciferol, 1 alpha, 25 dihydroxycholecalciferol and 24,25 dihydroxycholecalciferol on blood concentrations of 25 hydroxycalciferol, 25 dihydroxycholecalciferol, total calcium and eggshell quality. *British Poultry Science* **34** (5): 1021-7.

Tsang, C.P., Grunder, A.A., Soares, H. & Narbaitz, R. (1998) Effects of cholecalciferol or calcium deficiency of oestrogen metabolism in the laying hen. *British Poultry Science* **29**(4): 753-9.

Tsoukas, C.D., Provededini, D.M. & Manolagas, S.C. (1984) 1,25 dihydroxycholecalciferol; a novel immunoregulatory hormone. *Science* **224**: 1438-1440.

Tuan, R.S., Ono, T., Atkins, R.E. & Koide, M. (1991) Experimental studies on cultured, shell-less fowl embryos: calcium transport, skeletal development and cardiovascular functions. In: *Egg incubation: its effect on embryonic development in birds and reptiles*. (D.C. Deeming & M.W.Ferguson eds.), pp 419-433. Cambridge University Press. Cambridge, U.K.

Ullrey, D.E., Allen, M.E. & Baer, D.J. (1991) Formulated diets versus seed mixtures for psittacines. *Journal of Nutrition* **121** (11 Suppl): S193-205.

Ullrey, D.E. & Bernard, J.B. (1999) Vitamin D: Metabolism, sources, unique problems in zoo animals, meeting needs. In: *Zoo and Wild Animal Medicine Current Therapy*. (4th Edition, M.E. Fowler, R.E. Miller eds), pp 63-78. WB Saunders, Philadelphia, U.S.A.

Van de Velde, J.P., Loveridge, N. & Vermeiden, J.P. (1984) Parathyroid responses to calcium stress during eggshell calcification. *Endocrinology*. **115**: 1901-1904.

Wark, J.D., Taft, J.L., Michelangeli, V.P., Veroni, M.C. & Larkins, R.G. (1984) Biphasic action of prostaglandin E₂ on conversion of 25 hydroxyvitamin D₃ to 1,25 hydroxyvitamin D₃ in chick renal tubules. *Prostaglandins* **27** (3): 453-63.

Wasserman, R.H. & Taylor, A.N. (1966) Vitamin D₃-induced calcium binding protein in chick intestinal mucosa. *Science* **194**:791-793.

Wasserman, R.H. & Taylor, A.N. (1973) Intestinal absorption of phosphate in the chick: Effect of vitamin D₃ and other parameters. *Journal of Nutrition* **103**: 586-599.

Wasserman, R.H., Smith, C.A., Smith, C.M., Brindak, M.E., Fullmer, C.S., Krook, L., Penniston, J.T. & Kumar, R. (1991) Immunohistochemical localisation of a calcium pump and calbindin-D28K in the oviduct of the laying hen. *Histochemistry* **96**(5): 413-8.

Whitehead, C.C. (1989) Effects of vitamins on leg weakness in poultry. *Proceedings of 7th European Symposium on Poultry Nutrition*, pp 157-159 Loret de Mar Girona, Spain.

Wideman, R.F. Jr. & Youtz, S.L. (1985) Comparisons of avian renal responses to bovine parathyroid extract, synthetic bovine (1-34) parathyroid hormone and synthetic human (1-34) parathyroid hormone. *General Comparative Endocrinology* **57(3)**: 480-490.

Wideman, R.F. (1987) Renal regulation of avian calcium and phosphorus metabolism. *Journal of Nutrition* **117**: 808-815.

Wilkie, S.E., Vissers, P.M., Das, D., Degrip, W.J., Bowmaker, J.K. & Hunt, D.M. (1998) The molecular basis for UV vision in birds: spectral characteristics, cDNA sequence and retinal localisation of the UV-sensitive visual pigment of the budgerigar (*Melopsittacus undulatus*). *Biochemistry Journal* **330 (1)**: 541-7.

Williams, B., Waddington, D., Solomon, S. & Farquharson, C. (2000) Dietary Effects on bone quality and turnover, and calcium and phosphorus metabolism in chickens. *Research in Veterinary Science* **69(1)**: 81-87.

Williams, T.D., Reed, W.L. & Walzem, R.L. (2001) Egg size variation: mechanisms and hormonal control. In: *Avian Endocrinology* (A. Dawson & C.M. Chaturedi eds), pp 205-213. Alpha Science International Ltd., Pangbourne, UK.

Wilson, S. & Duff, S.R. (1991) Effects of vitamin or mineral deficiency on the morphology of medullary bone in laying hens. *Research in Veterinary Science* **50 (2)**: 216-21.

Wise, D. (1975) Skeletal abnormalities in table poultry; a review. *Avian Pathology* **4**: 1-10.

Woodward, J. (1996) Metabolic bone disease. In: *Veterinary Pathology* (Jones, Hunt and King), pp 915-923. Lippencott, Williams and Wilkins, Philadelphia, U.S.A.

Xu, T., Leach, R.M., Hollis, B. & Soares, J.H. (1997) Evidence of increased cholecalciferol requirement in chicks with tibial dyschondroplasia. *Poultry Science* **76(1)**: 47-53.

Yang, H.S., Waibel, P.E. & Brenes, J. (1973) Evaluation of vitamin D3 supplements by biological assay using the turkey. *Journal of Nutrition* **103**: 1187-1194.

Yarden, N., Lavelin, I., Genina, O., Hurwitz, S., Diaz, R., Brown, E.M. & Pines, M. (2000) Expression of calcium-sensing receptor gene by avian parathyroid gland in vivo: relationship to plasma calcium. *General Comparative Endocrinology* **117 (2)**: 173-81.

Yarger, J.G., Saunders, C.A., McNaughton, J.L., Quarles, C.L., Hollis, B.W. & Gray, R.W. (1995) Comparison of dietary 25 hydroxycholecalciferol and cholecalciferol in broiler chickens. *Poultry Science* **74(7)**: 1159-67.

